

DAFTAR PUSTAKA

- [1] V. Filippou dan C. Tsoumpas. “Recent advances on the development of phantoms using 3D printing for imaging with CT, MRI, PET, SPECT and Ultrasound”, *Medical Physics*, Vol.45, No.9:740-741, 2018.
- [2] R. Latifah, N. Z. Jannah, D. Z. I Nurdin, dan P. Budi. “Determination of Local Diagnostic Reference Level (LDL) Pediatric Patients on CT Head Examination Based on Size-Specific Dose Estimates (SSDE) Values”. *Journal of Vocational Health Studies*, Vol.2, No.3:127-128, 2019.
- [3] B. O. Botwe, *et al.* “National Indication-Based Diagnostic Reference Level Values in Computed Tomography: Preliminary Results from Ghana”. *Physica Medica*, Vol.84, No.28:274-279, 2021.
- [4] C. Clerkin, S. Brennan, dan L. M. Mullaney. “Establishment of National Diagnostic Reference Levels (DRLs) for Radiotherapy Localisation Computer Tomography of the Head and Neck”. *Reports of Practical Oncology & Radiotherapy*, Vol.23, No.5:408, 2018.
- [5] M. K. Abdulkadir, *et al.* “Evaluation of Age-Based Radiation Dose in Paediatric Patients Received from Head CT Examination at a Tertiary Hospital, Nigeria”. *Radiation Physics and Chemistry*, Vol.182, No.2:1-5, 2021.
- [6] M. A. S. M Razali, M. Z. Ahmad, I. L. Shuaib, dan N. D. Osman. “Optimization Of Radiation Dose In CT Imaging: Establishing The Institutional Diagnostic Reference Levels and Patient Dose Auditing”. *Radiation Protection Dosimetry*, Vol.188, No.22:1-8, 2019.
- [7] X. Wang, *et al.* “A Deep Learning Algorithm for Automatic Detection and Classification of Acute Intracranial Hemorrhages in Head CT Scans”. *NeuroImage: Clinical*. Vol.32:2, 2021.
- [8] M. K. A. Karim, *et al.* “Paediatric Radiation Dose and Cancer Risk Associated with Body Effective Diameter During CT Thorax Examination”. *Radiation Physics and Chemistry*. Vol.188, hal: 1-2, 2021.

- [9] A. Fabijanska. "Segmentation of Pulmonary Vascular Tree from 3D CT Thorax Scans". *Biocybernetics And Biomedical Engineering*. Vol.35, No.2:1-2, 2014.
- [10] S. Z. Rahmadani, S. Masrochah, dan A. S. Wibowo. *Prosedur Pemeriksaan Computed Tomography (CT) Scan Abdomen Tiga Fase Dengan Kasus Ca Sigmoid Di Instalasi Radiologi Rsud Dr.Soedono Madiun*. Skripsi. Program Studi DIV T. Radiodiagnostik dan Radioterapi, Poltekkes Kemenkes Semarang, Semarang, 2017.
- [11] L. Stanhope dan K. Turnbull. *Introducton to Medical Terminology, 1st Edition*. The Goodheart Willcox Company, United States of America, 2017.
- [12] E. BR Tarigan. *Analisis Dosis Radiasi Pada Pemeriksaan CT-Scan Thorax*. Skripsi. Program Studi Fisika, Fakultas Matematika dan Ilmu Pengetahuan Alam, Universitas Sumatera Utara, Medan, 2019.
- [13] E. Samei dan N. J. Pelc. *Computed Tomography Approaches, Applications, and Operations*. Springer Nature Switzerland. 2020.
- [14] Rusmanto dan I. Syafitri. *Pedoman Teknis Penyusunan Tingkat Panduan Diagnostik Atau Diagnostic Reference Level (DRL) Nasional*. Badan Pengawas Tenaga Nuklir, Jakarta, 2019.
- [15] A. S. Pratikno, A. A. Prastiwi, dan S. Ramahwati. "Kuartil, Desil, dan Presentil Serta Cara menghitungnya dalam Dsitribusi Frekuensi". *OSF Preprints*. Vol.23, No.3, 2020.
- [16] P. Roch, D. Celier, C. Dessaud, dan C. Etard. "Using Diagnostic Reference Levels to Evaluate The Improvement of Patient Dose Optimisation and The Influence of Recent Technologies in Radiography and Computed Tomography". *European Journal of Radiology*. Vol.98, hal:68, 2018.
- [17] R. Suryanti. L. Savitri, W. Susanto, I. Syafitri, Iswandarini, E. Kunarsih, Rusmanto, IB Gede Putra. *Manual Penggunaan Si-INTAN Ver. 2.0*. P2STPFRZR BAPETEN, Jakarta, 2018.
- [18] BAPETEN. *Tingkat Panduan Diagnostik Indonesia Profil Dosis Tahunan*, Diakses dari <https://idrl.bapeten.go.id/index.php/site/idrl> , 30 Agustus 2022.

LAMPIRAN 1

TAMPILAN NILAI DRL CT-SCAN 2018 PADA WEBSITE Si-INTAN

SiNTAN English Home BERANDA TENTANG DRL BERITA FAQ HUBUNGI KAMI LOGIN

PROFIL DOSIS RADIASI PASIEN TAHUNAN CT SCAN
2018

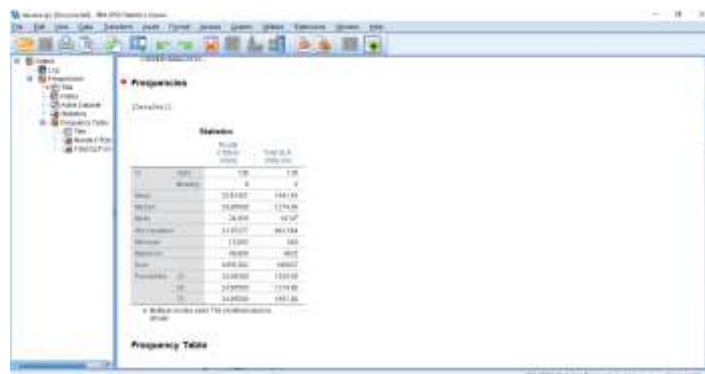
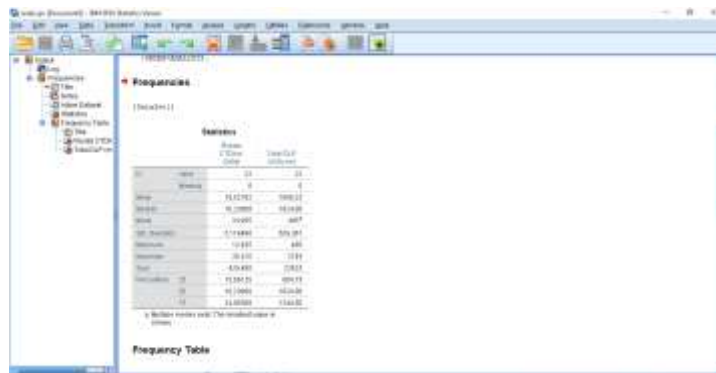
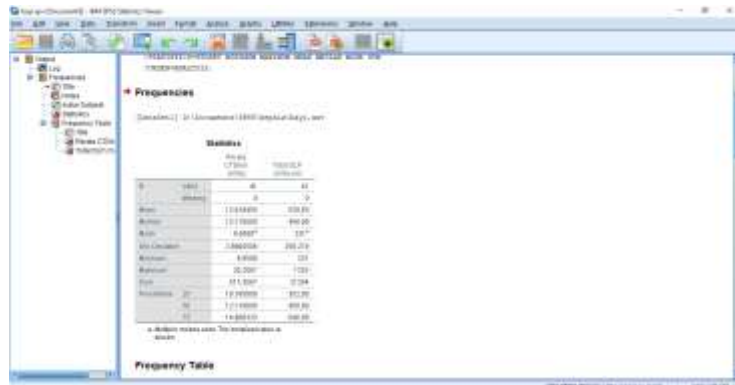
CTDIvol (mGy)				
No	Jenis Pemeriksaan	0-4	5-14	15-24
1	CT ABDOMEN	15	18	20
2	CT ABDOMEN FLAIRING	-	-	13
3	CT AbdoPelvis	14	14	17
4	CT Calcium Score	-	-	12
5	CT Cardiac Studies	-	-	24
6	CT Cervical Thoracic	-	-	14
7	CT Chest	-	14	14
8	CT ChestAbdoPelvis*	-	-	27
9	CT Extremities	-	-	13
10	CT Head	64	61	63
11	CT HEAD AND NECK PLANNING	-	-	26
12	CT Larynx/Neckopharynx	-	-	38
13	CT Mastoids	-	-	38
14	CT Neck	-	-	67
15	CT Orbit	-	-	68
16	CT PELVIS PLANNING	-	-	13
17	CT Urology	-	-	20
18	CTA Head	-	-	39
19	Spine CT	-	-	38

DLP (mGy cm)				
No	Jenis Pemeriksaan	0-4	5-14	15-24
1	CT ABDOMEN	384	744	1164
2	CT ABDOMEN FLAIRING	-	-	892
3	CT AbdoPelvis	624	563	1350
4	CT Calcium Score	-	-	191
5	CT Cardiac Studies	-	-	942
6	CT Cervical Thoracic	-	-	623
7	CT Chest	-	443	759
8	CT ChestAbdoPelvis*	-	-	1180
9	CT Extremities	-	-	890
10	CT Head	1430	1391	2400
11	CT HEAD AND NECK PLANNING	-	-	1064
12	CT Larynx/Neckopharynx	-	-	1530
13	CT Mastoids	-	-	1179
14	CT Neck	-	-	2713
15	CT Orbit	-	-	1938
16	CT PELVIS PLANNING	-	-	566
17	CT Urology	-	-	1081
18	CTA Head	-	-	1849
19	Spine CT	-	-	394

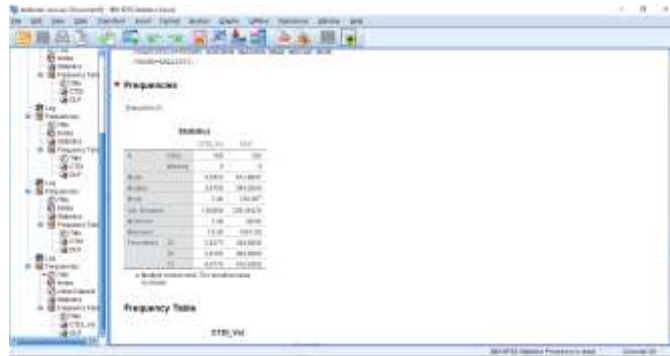
LAMPIRAN 2

KELUARAN DISTRIBUSI NILAI CTDI_{Vol} dan DLP PADA SOFTWARE SPSS

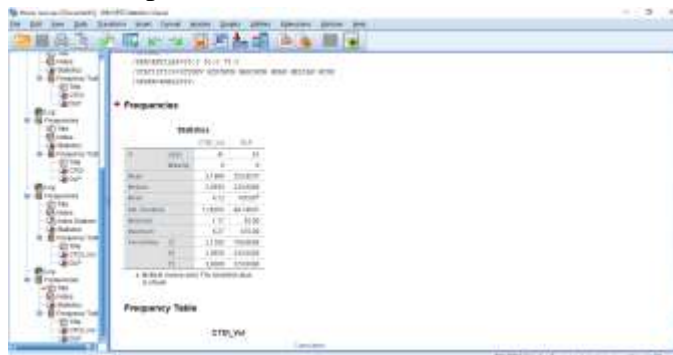
1. Pemeriksaan Kepala pada Usia Bayi, Anak, dan Dewasa di RS. Wahidin Sudirohusodo



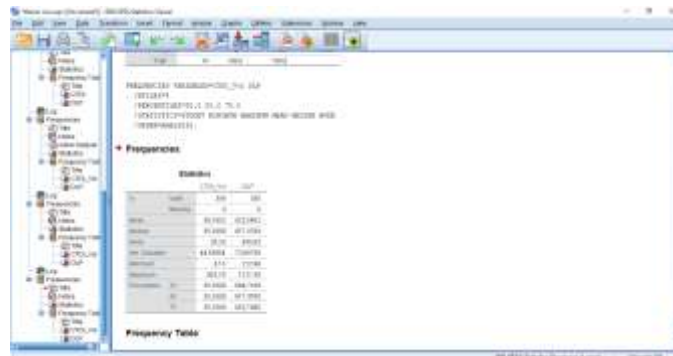
2. Pemeriksaan Abdomen pada Usia Dewasa di RS. Wahidin Sudirohusodo



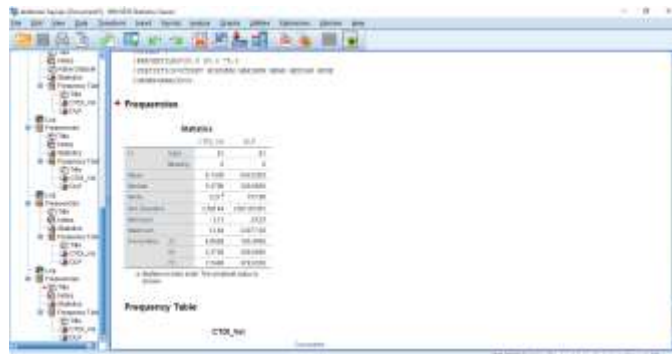
3. Pemeriksaan Thorax pada Usia Dewasa di RS. Wahidin Sudirohusodo



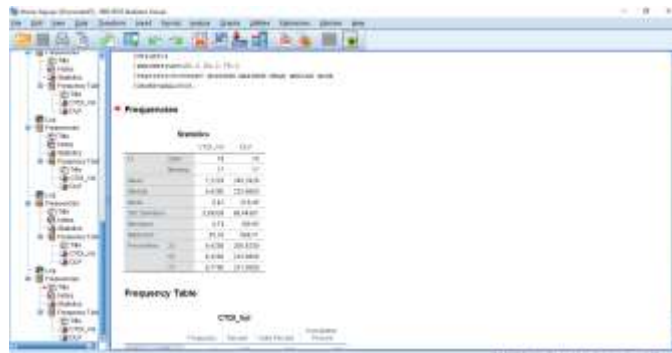
4. Pemeriksaan Kepala pada Usia Dewasa di RS. Haji Makassar



5. Pemeriksaan Abdomen pada Usia Dewasa di RS. Haji Makassar

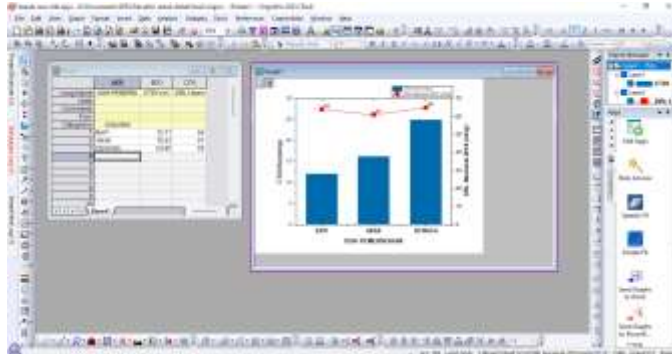


6. Pemeriksaan Thorax pada Usia Dewasa di RS. Haji Makassar

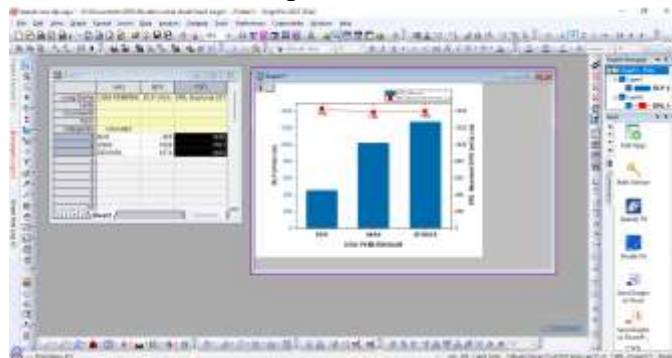

LAMPIRAN 3
KELUARAN GRAFIK PADA SOFTWARE ORIGIN

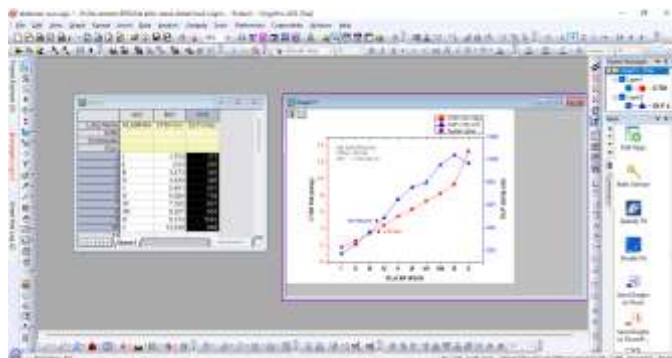
1. Grafik Nilai CTDI_{Vol} Pemeriksaan Kepala di RS. Wahidin Sudirohusodo



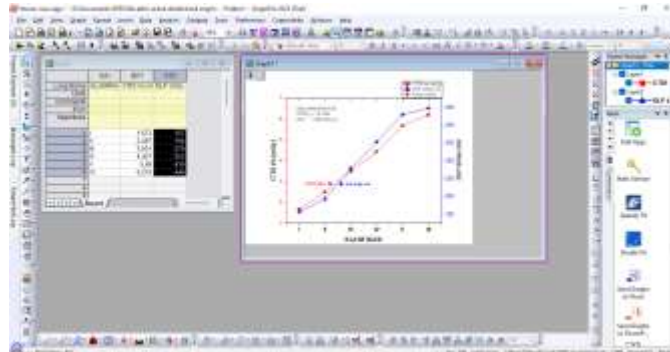
2. Grafik Nilai DLP Pemeriksaan Kepala di RS. Wahidin Sudirohusodo



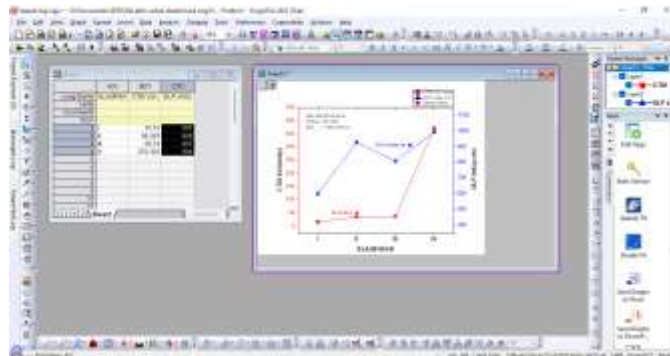
3. Grafik Nilai CTDI_{Vol} dan DLP Pemeriksaan Abdomen di RS. Wahidin Sudirohusodo



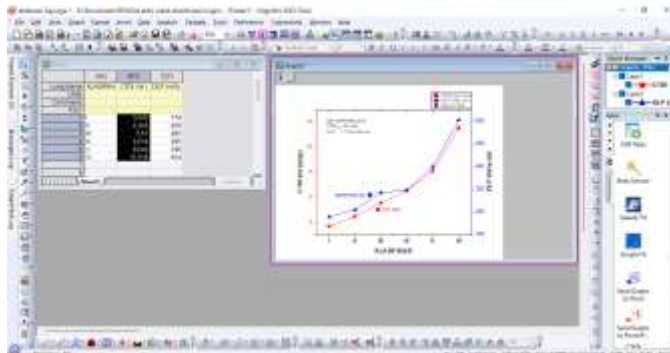
4. Grafik Nilai CTDI_{Vol} dan DLP Pemeriksaan Thorax di RS. Wahidin Sudirohusodo



5. Grafik Nilai CTDI_{Vol} dan DLP Pemeriksaan Kepala di RS. Haji Makassar



6. Grafik Nilai CTDI_{Vol} dan DLP Pemeriksaan Abdomen di RS. Haji Makassar



7. Grafik Nilai CTDI_{Vol} dan DLP Pemeriksaan Thorax di RS. Haji Makassar

