

DAFTAR PUSTAKA

- Agudelo VV, Cardona-arias JA. *Meta-analysis of the utility of culture, biopsy, and direct KOH examination for the diagnosis of onychomycosis*. BMC Infectious Diseases. 2017
- Akkus, G., Evran, M., Gungor, D., Karakas, M., Sert, M., & Tetiker, T. (2016). Tinea pedis and onychomycosis frequency in diabetes mellitus patients and diabetic foot ulcers. *Pakistan journal of medical sciences*, 891-895.
- Amanda, C. M. 2019. *Hubungan Antara Onikomikosis Dengan Kadar Superoxide Dismutase*. Program Pendidikan Dokter Spesialis Departemen Dermatologi Dan Venerologi. Fakultas Kedokteran Universitas Sumatera Utara. Medan
- Ameen M, Lear JT, Madan V, Mustapa MF, Richardson M. British Association of Dermatologists' guidelines for the management of onychomycosis 2014. *British Association of Dermatologists*. 2014;171:937-58
- Baran R, Hay Roderick, Heneke E, Tosti A. 1999. *Mycological examination. Onychomycosis. 2nd edition*. 49-68
- Bintari, N. W. D., Suarsana, A., dan Wahyuni, P. R. (2019). *Onychomycosis NonDermatofita Pada Peternak Babi di Banjeng Paang Kaja dan Banjar Semaga Desa Penatih Kecamatan Denpasar Timur*. *Jurnal Kesehatan Terpadu*, 3(1), 8–14.
- Bramono K, Budimulja U. Epidemiology of onychomycosis in Indonesia: Data obtained from three individual studies. *Japanese Journal of Medical Mycology*. 2005; 46: 171-176.
- Bramono K. Onikomikosis. In: Bramono K, Suyoso S, Indriatmi W, Ramali LM, Widaty S, Ervianti E, editors. *Dermatomikosis Superfisialis* (2nd ed). Jakarta: Badan penerbit Fakultas Kedokteran Universitas Indonesia, 2013; p. 86-99
- Budimulja, U., Djuanda, A., Hamzah, M., & Aisah, A. (2007). *Ilmu Penyakit Kulit dan Kelamin (5th ed.)*. Fakultas Kedokteran Universitas Indonesia.
- Daniel III C, Jellinek N, Rubin A, Scher R. *Scher and Daniel's Nails*. 4th ed. Switzerland: Springer International Publishing; 2018.
- Ghannoum M, Mukherjee P, Isham N, Markinson B, Rosso JD, Leal L. Examining the importance of laboratory and diagnostic testing when treating and diagnosing onychomycosis. *The International Society of Dermatology*. 2017
- Gregoriou, S., Mpali, N., Vrioni, G., Hatzidimitriou, E., Chryssou, S., & Rigopoulos, D. (2020). Epidemiology of Onychomycosis in an Academic Nail Unit in South Greece during a Three-Year Period. *Skin appendage disorders*, 102-107.



- Gupta, A., Gupta, G., Jain, H., Lynde, C., Foley, K., Daigle, D., . . . Summerbell, R. (2016). The prevalence of unsuspected onychomycosis and its causative organisms in a multicentre Canadian sample of 30 000 patients visiting physicians' offices. *Journal of the European Academy of Dermatology and Venereology*, 1567-1572.
- Gupta, A., Mays, R., Versteeg, S., Shear, N., & Piguët, V. (2018). Update on current approaches to diagnosis and treatment of onychomycosis. *Expert review of anti-infective therapy*, 929-938.
- Hay RJ, Baran R. Onychomycosis : a proposed revision of the clinical classification. *J Am Acad Dermatol* 2011; 65 (6): 1219-1227.
- Hay RI, Moore MK. Mycology. In: Burn T, Breahnatch S, Cox N, Griffiths C, editors. *Rook's Textbook of Dermatology* (8th ed). Oxford: Blackwell Publishing, 2010; p. 36.56-64.
- Hay, R., & Baran, R. (2011). Onychomycosis: a proposed revision of the clinical classification. *Journal of the American Academy of Dermatology*, 1219-1227.ⁱ
- Hoy, N., Leung, A., Metelitsa A. I., & Adams, S. (2012). New Concepts in Medial Nail Dystrophy Onychomycosis, and Hand, Foot, and Mouth Disease Nail Pathology. *ISRN Dermatology*.
- Kang S, Amagai M, Bruckner AL, Enk AH, Margolis DJ, McMichael AJ, Orringer JS. *Fitzpatrick's Dermatology*, 9th Edition. New York: McGraw-Hill, 2019, pp. 2925-2950.
- Karmila, I. G. A. A. D., Adiguna, M. S., & Rusyati, L. M. M. (2020). Profil onikomikosis pada pasien lanjut usia di Rumah Sakit Umum Pusat Sanglah, Bali, Indonesia: studi retrospektif. *Intisari Sains Medis*, 11(1), 364. <https://doi.org/10.15562/ism.v11i1.653>
- Kaur R, Kashyap B, Bhalla P. Onychomycosis- epidemiology, diagnosis and management. *Indian Journal of Medical Microbiology*. 2008; 26 (2): 108-16
- Kuvandik, G., Cetin, M., Genctoy , G., Horoz , M., Duru, M., Akcali, M., . . . Kaya, H. (2007). The prevalence, epidemiology and risk factors for onychomycosis in hemodialysis patients. *BMC Infectious Diseases*.
- Lipner, S., & Scher, R. (2018). Onychomycosis : Clinical overview and diagnosis. *Journal of the American Academy of Dermatology*, 835-851.
- Melnick, J. A. (2017). *Mikrobiologi Kedokteran*. Jakarta: Buku Kedokteran EGC.
- MirobeHolic. (2020). *Sabouraud Dextrose Agar (SDA) - Definisi, Komposisi, Cara Pembuatan dan Interpretasi Uji* . Retrieved Juni Rabu, 2020




- Navin Raj. 2017. Identifikasi Jamur Pada Kuku Jari Tangan Mahasiswa Angkatan 2013 Fakultas Kedokteran Universitas Sumatera Utara. Fakultas Kedokteran Universitas Sumatera Utara. Medan
- Noguchi, H., Matsumoto, T., Kimura, U., Hiruma, M., Kano, R., Yaguchi, T., & Ihn, H. (2020). Non-dermatophyte Mould Onychomycosis in Japan. *Medical Mycology Journal*, 61, 23-31.
- Noviandini, A., Suyoso, S., & Astari, L. (2017). Pemeriksaan Pewarnaan Kalium Hidroksida (KOH) 20% + Tinta Parker Blue-Black, Chicago Sky Blue (CSB), dan Kultur Jamur pada Dermatofitosis Superfisialis. *Berkala Ilmu Kesehatan Kulit Dan Kelamin*, 29(1), 21–30.
- Piraccini, B., & Alessandrini, A. (2013). Drug-related nail disease. *Clin Dermatol*, 618-626.
- Poluri, L., Indugula, J., & Kondapaneni, S. (2020). Clinicomycological Study of Dermatophytosis in South India. *Journal of Laboratory Physicians*, 84-89.
- Putri G. 2017. Kualitas Hidup Pada Pasien Onikomikosis. Program Magister Kedokteran Klinik Departemen Ilmu Kesehatan Kulit Dan Kelamin. Fakultas Kedokteran Universitas Sumatera Utara. Medan
- Richardson MD, Warnock DW, editors. *Fungal Infection Diagnosis and Management* (4th ed). Chichester: John Wiley & Sons, 2012; p. 21-23,128,135.
- Rigopoulos, D., Papanagiotou, V., Daniel , R., & Piraccini, B. (2017). Onychomycosis in patients with nail psoriasis: a point to point discussion. *Mycoses*, 6-10.
- Rizal, F., 2011. Sensitifitas Dan Spesifisitas Pewarnaan Periodic Acid Schiff (PAS) Dan Kultur Untuk Mendiagnosis Onikomikosis. Available from: <http://repository.usu.ac.id/handle/123456789/23005>
- Rizky, A., Thaha, M. A., & Rusmawardiana, R. (2015). Nilai Diagnostik Dermatophyte Strip Test pada Pasien Tinea Unguim. *Jurnal Kedokteran Dan Kesehatan*, 2(1), 99–103.
- Rohmah, A. I. N., & Bariyah, K. (2012). *Kualitas Hidup Lanjut Usia*. *Jurnal Keperawatan*, 3(2), 120–132.
- Schieke SM, Garg A. Superficial fungal infection. In: Wolff K, Goldsmith LA, Katz SI, Gilchrest BA, Paller AS, Leffell DJ, editors. *Fitzpatrick's Dermatology in General Medicine* (8th ed). New York: Mc Graw Hill Inc, 2012; p. 2292-7.
- Setianingsih, I., Arianti, D. C., & Fadilly, A. (2015). *Prevalensi, Agen Penyebab, dan Analisis Faktor Resiko Infeksi Tinea unguim pada peternak Babi di Kecamatan, Tanah Siang, Provinsi Kalimantan Tengah*. *Jurnal Epidemiologi Dan Penyakit Bersumber Binatang*, 5(3), 155–161.

- Shemer A. Update: Medical treatment of onychomycosis. *Dermatol Ther* 2012; 25: 582-593
- Shenoy, M., Teerthanath, S., Karnaker, V., Girisha, B., Prasad, M., & Pinto, J. (2008). Comparison of potassium hydroxide mount and mycological culture with histopathologic examination using periodic acid-Schiff staining of the nail clippings in the diagnosis of onychomycosis. *Indian J Dermatol Venereol Leprol*, 74, 226-229.
- Singal A, Khanna D. Onychomycosis: diagnosis and management. *IJDVL* [Internet]. 2011.[cited 2015 January 13];77(6):659-72.
- Thomas, J., Peterson, G., Christenson, J., Kosari, S., & Baby, K. (2019). Antifungal Drug Use for Onychomycosis. *American journal of therapeutics*, 388-396.
- Trofa D, Gacser A, Nosanchuk JD. *Candida parapsilosis*, an emerging fungal pathogen. *Clin Microbiol Rev*. 2008; 21(4): 606-625.
- Verma S, Hefferman MP. Superficial Fungal Infection: Dermatophytosis, Onychomycosis, Tinea Nigra, Piedra. In: Wolff K, Goldsmith L, Katz S, Gilchrest B, Paller A, Leffell O, editors. *Fitzpatrick's Dermatology in General Medicine*. 7th ed. New York: McGraw-Hill; 2008. p. 1807–21.
- Verma S, Hefferman MP. Superficial Fungal Infection: Dermatophytosis, Onychomycosis, Tinea Nigra, Piedra. In: Wolff K, Goldsmith L, Katz S, Gilchrest B, Paller A, Leffell O, editors. *Fitzpatrick's Dermatology in General Medicine*. 7th ed. New York: McGraw-Hill; 2008. p. 1807–21.
- Vlahovic, T. (2016). Onychomycosis: Evaluation, Treatment Options, Managing Recurrence, and Patient Outcomes. *Clinics in podiatric medicine and surgery*, 33 (3), 305-318.
- Wolff K, Johnson R, Saavedra A, Roh E. *Fitzpatrick's Color Atlas and Synopsis of Clinical Dermatology*, 8th Edition. New York, N.Y.: McGraw-Hill Education LLC.; 2017. Pp 824-827.
- Wolff, K. L., & Johnson, R. A. (2010). *Fitzpatrick's Color Atlas & Synopsis of Clinical Dermatology* (6th ed.). McGraw-Hill Companies.

LAMPIRAN

Gambar klinis kuku

Klinis	Foto	Penulis
Distal and lateral subungual onychomycosis disebabkan oleh <i>T. rubrum</i>		(Hay and Baran, 2011)
Superficialis onychomycosis disebabkan oleh <i>T. mentagrophytes</i> .		(Hay and Baran, 2011)

<p>Onikomikosis endoniks disebabkan oleh <i>T. soudanense</i></p>		<p>(Hay and Baran, 2011)</p>
<p>Onikomikosis subungual proksimal disebabkan oleh <i>C. albicans</i> sebabkan paronikum</p>		<p>(Hay and Baran, 2011)</p>
<p>Onikomikosis distropik total</p>		<p>(Hay and Baran, 2011)</p>

Gambaran Mikroskopik dengan KOH 20%

Positif	Negatif
	

KUISIONER PENELITIAN

“Karakteristik Infeksi Jamur Kuku Pada Pedagang Pasar Tradisional Terong Makassar”

A.IDENTITAS RESPONDEN

Isilah identitas diri saudara dengan keadaan yang sebenarnya :

- a. No.Responden : _____
- b. Nama (Sesuai KTP) : _____
- c. Jenis kelamin : _____
- d. Usia : _____
- e. No telepon : _____
- f. Alamat : _____

B.PERTANYAAN PENELITIAN

1.Lama berjualan : _____

2.Jenis jualan : 1. Ikan

2. Ayam/daging
3. Sayuran/buahan
4. Kelontong
5. Pakaian bekas/ pakaian baru
6. Makanan jadi

3. Penampakan kebersihan kuku :

4. jika terdapat kelainan kuku :

1. Lokasi kelainan kuku
2. Sejak kapan muncul
3. Kuku bagian mana pertama muncul
4. Kuku apa saja yang mengalami kelainan
5. Warna kuku

5. Faktor pencetus :

1. Psoriasis
2. Kencing manis
3. Hipertensi
4. Trauma berulang
5. Penyakit imunodefisiensi

6. Apakah Anda memiliki kelainan kulit di bagian tubuh yang lain?

1. Ya
2. Tidak

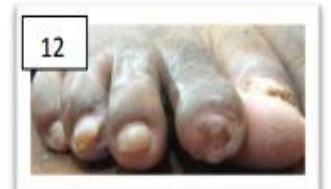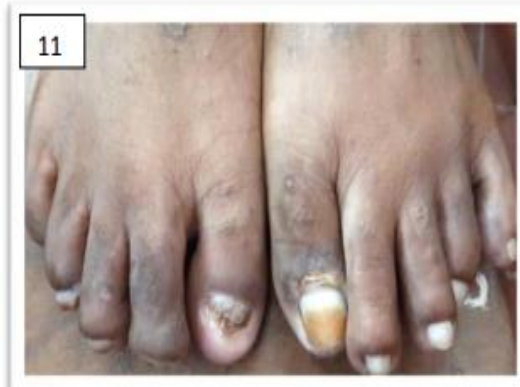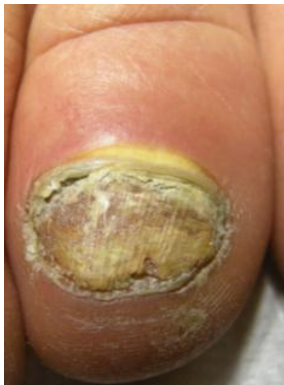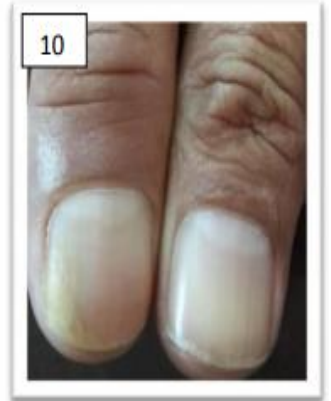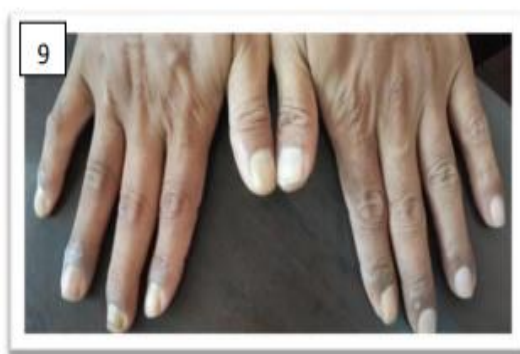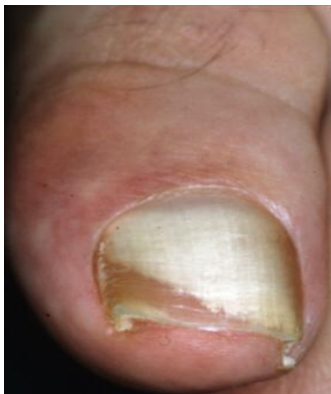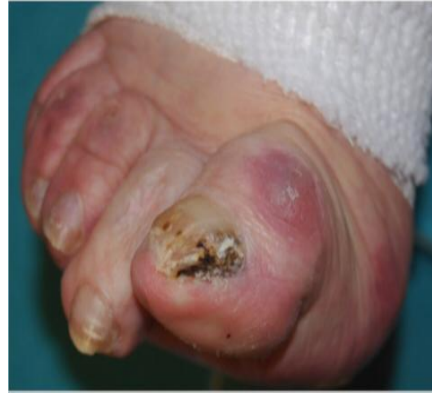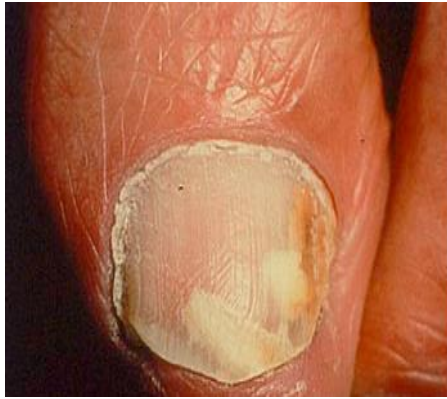. 7. Jika terdapat kelainan kulit:

1. Apakah gatal
2. Berbatas tegas
3. Berwarna merah atau putih
4. Bersisik

8. Apakah saudara menjawab pertanyaan diatas dengan keadaan yang sebenarnya?

1. Ya
2. Tidak

Gambar Infeksi Jamur Kuku



LAMPIRAN

2.11 *Lampiran 1. Curriculum Vitae* Penulis



Identitas Pribadi

Nama : Muhammad Iftikhar Musa'ad
NIM : C011181550
Tempat, Tanggal Lahir : Jayapura, 9 juli 2000
Agama : Islam
Suku : -
Alamat : Cibubur Country CC.OR 22
Nomor Telepon : 081314390797
E-mail : ivanmusaad@gmail.com

Identitas Orang Tua

Nama Ayah : Dr. Drs. H. Muhammad Musa'ad., M.Si
Nama Ibu : Hj. Andar Aryani., SH, MH.
Alamat Orang Tua : Cibubur Country CC.OR 22
Pekerjaan Ayah : ASN
Pekerjaan Ibu : ASN
Anak ke : Empat

Riwayat Pendidikan

Jenjang	Nama Sekolah	Tahun
SD	SDN Jatisampurna I	2006 – 2012

SMP	SMPIT Al-Ishmah	2012 - 2015
SMA	SMA Pribadi Bandung	2015 - 2018
S1	Fakultas Kedokteran Universitas Hasanuddin	2018-sekarang

Riwayat Organisasi

	Jabatan	Periode
Himpunan Mahasiswa Islam	Ketua Umum	2020 -2021
