



Case report

Tuberculosis of the knee masquerading as pigmented villonodular synovitis: Report of two cases

Muhammad Phetrus Johan^{a,*}, Imeldy Prihatni Purnama^b, Iswahyudi Nurdin^a,
Ahmad Perdana Asy'arie^a, Arian Fardin Ignatius Wawolumaja^a, Tomohiko Sakuda^c

^a Department of Orthopaedics and Traumatology, Dr. Wahidin Sudirohusodo General Hospital - Faculty of Medicine Hasanuddin University, Makassar, Indonesia

^b Department of Pathology Anatomy, Dr. Wahidin Sudirohusodo General Hospital - Faculty of Medicine Hasanuddin University, Makassar, Indonesia

^c Department of Orthopaedic Surgery, Graduate School of Biomedical and Health Sciences, Hiroshima University, 1-2-3 Kasumi, Minami-ku, Hiroshima 734-8551, Japan

ARTICLE INFO

Keywords:

Tuberculosis of the knee
Gonitis
Pigmented villonodular synovitis
Case report

ABSTRACT

Introduction and importance: The manifestation of tuberculous mimicry is challenging to diagnose, especially in extrapulmonary Tuberculosis (TB). Pigmented villonodular synovitis (PVNS) may mimic tuberculous arthritis of the knee joint. In young, otherwise healthy-appearing individuals, tuberculous arthritis and PVNS in the knee joint could present as monoarticular involvement, with painful swelling of extended duration and limited movement. The core therapies for tuberculous arthritis and PVNS are different.

Case presentation: There are two patients. First, male 25 years old presented with a painful mass at the left knee of 3-years duration. The second patient was 14 years old boy who presented with a painful mass at his left knee for ten months before being admitted to the hospital. From the physical examination, plain x-ray, and MRI, both patients are highly suggestive of PVNS. However, the histopathology result and microbial culture showed a tuberculous-specific process.

Clinical discussion: Because of its clinical manifestations, X-ray, and MRI features, patients were initially suspected of having the diffuse type of PVNS. An improper diagnosis may be due to atypical clinical presentation, wide use of antibiotics, the low specificity of diagnostic tools, and most of all, the clinician not prioritizing the possibility of tuberculous arthritis. Open biopsy and the result of the microbial culture establish the definitive diagnosis of knee tuberculosis.

Conclusion: In conclusion, the clinical and radiologic findings in TB gonitis and PVNS are occasionally similar. Therefore TB gonitis should be highly suspicious, especially in endemic areas. Histopathology results and mycobacterial culture need to determine the diagnosis.

1. Introduction

Tuberculosis (TB) has been recognized as a disease with many mimicry clinical manifestations that often lead to misdiagnosis. In 2019 Indonesia was the third country with the highest prevalence of tuberculosis [1]. Skeletal involvement was seen in 1% to 3% of patients with TB and approximately 10–20% of extrapulmonary cases. About one-half of these affect the spine, and the rest are extraspinal osteoarticular joints. The knee is the third most common musculoskeletal site after the spine and hip [2–6]. Mimicries manifestation of the TB provides difficulties in diagnosing it, particularly in extrapulmonary TB [1]. Extrapulmonary TB was usually diagnosed late due to lack of familiarity with

the disease, indolent course of the illness, and varied clinical presentation and radiographic appearance [1,7].

Tuberculous arthritis of the knee joint may mimic pigmented villonodular synovitis (PVNS) [7]. Both tuberculous arthritis and PVNS in the knee joint of young, otherwise healthy-appearing individuals may present as monoarticular involvement with painful swelling of extended duration (usually more than several months to years) and limited motion. In the MRI study, both conditions show synovial proliferation, reactive bone marrow edema, and cortical erosion [7,8]. Delayed treatment of either disease can result in severe cartilage destruction or high-grade joint deformation.

PVNS is a benign proliferative disorder that affects synovial lined

* Corresponding author at: Department of Orthopaedics and Traumatology, Dr. Wahidin Sudirohusodo General Hospital - Faculty of Medicine Hasanuddin University, Makassar, Indonesia, Jl. Perintis Kemerdekaan Km 10, Hasanuddin University Hospital 3rd Floor, Makassar, Indonesia.

E-mail address: muhpjo@gmail.com (M.P. Johan).

<https://doi.org/10.1016/j.ijscr.2021.106534>

Received 13 September 2021; Received in revised form 16 October 2021; Accepted 16 October 2021

Available online 23 October 2021

2210-2612/© 2021 Published by Elsevier Ltd on behalf of IJS Publishing Group Ltd. This is an open access article under the CC BY-NC-ND license

(<http://creativecommons.org/licenses/by-nc-nd/4.0/>).

joints, bursa, and tendon sheaths. There are two primary forms: a localized and diffuse form that affects the entire synovial lining of a joint, bursa, or tendon sheath. Although a benign condition, the disorder may result in bone destruction and proliferate to surrounding structures if left untreated [9]. The mainstays of treatment for tuberculous arthritis and PVNS are different [7]. Therefore, distinguishing between these two disease entities is very important for patient outcomes. The present report describes two patients with TB agonists, in whom the clinico-radiological findings were similar to that of PVNS. The work has been reported in line with SCARE 2020 criteria. [10]

2. Presentation of case

There are two patients. First, male 25 years old presented with a painful mass at the left knee of 3-years duration. The mass was growing gradually from as big as marble into the size of an egg. The pain was aggravated by the movement of the knee joint. The patient was treated with intermittent non-steroidal anti-inflammatory medication at a local clinic. The treatment slightly improved symptoms but did not subside completely, and he was referred to our hospital to evaluate these unexplained symptoms. Initial examination revealed moderate soft tissue enlargement and pain at the left knee joint, with no definite redness and fever (Fig. 1A). His range motion was 20–60°. The blood test showed a leukocyte count of 9.0×10^3 per mm^3 . Plain anteroposterior and lateral radiographs of the left knee joint revealed soft tissue swelling with no bony abnormality (Fig. 1B). MRI examination revealed heterogeneous lesions at T1-weighted and T2-weighted images. The region of synovial thickening and irregularity in the suprapatellar area was found on MRI. The lesion demonstrated extra-articular spread, including the posterior

cruciate ligament and popliteus tendon region, highly suggestive of PVNS (Fig. 1C). Based on the clinical examination and imaging studies, the patient was initially diagnosed with PVNS of the diffuse type. A fine-needle aspiration biopsy was done and revealed an inflammation lesion. The examination continued with an open biopsy and showed proliferative synovium with epithelioid granuloma and Datia Langhans cells (Fig. 1D). The conclusion for open biopsy examination is chronic granulomatous inflammation suitable for a tuberculous process. Nevertheless, the patient lost to follow up one month after receiving the anti-tuberculosis drugs.

The second patient was 14 years old boy who presented with a painful mass at his left knee for ten months before being admitted to the hospital. In the beginning, the mass sized as marble then grew as significant as a tennis ball without redness and no fever (Fig. 2A). The range motion of the left knee was measured at 0°–20°. The blood test showed a leukocyte count of 7.7×10^3 per mm^3 . A plain radiograph showed soft tissue swelling without any abnormality at the bone (Fig. 2B). MRI findings showed intermediate signal intensity on T1 and T2 weighted scans of the lesions at Hoffa pad region, suprapatellar bursa, popliteal bursa, and low signal intensity indicative of hemosiderin deposits. All the features were informative for PVNS diagnosis of the patient's left knee (Fig. 2C). However, histopathology results from the open biopsy showed granuloma, wide caseating necrosis, and some Datia Langhans cell leading to chronic specific granulomatous inflammation (Fig. 2D). Other samples were brought to the laboratory for culture, which resulted in a positive result for *mycobacterium tuberculosis*. Because the pathology showed a specific tuberculous process, the Gonitis Tuberculosa was established as the final diagnosis. The treatment initially prescribed was an empirical anti-tuberculous regimen

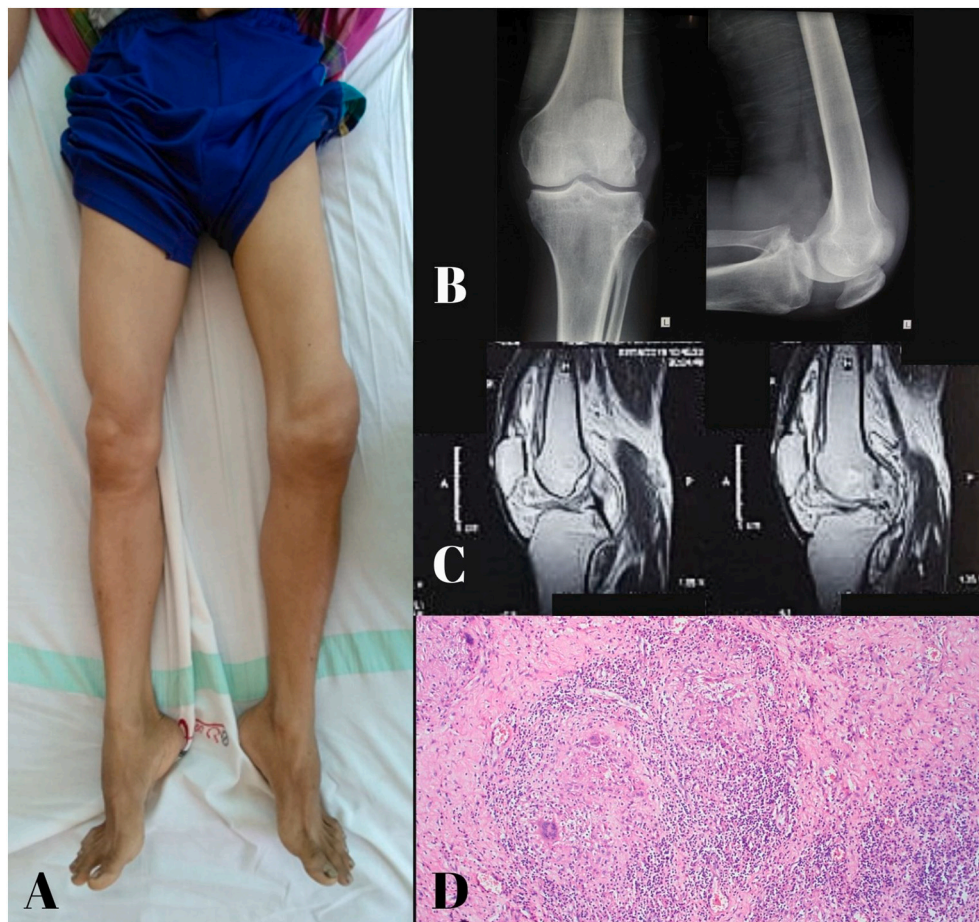


Fig. 1. Clinical appearance of the left knee (A); plain Xray (B); MRI (C); and Histopathology result (D) of the first patient.

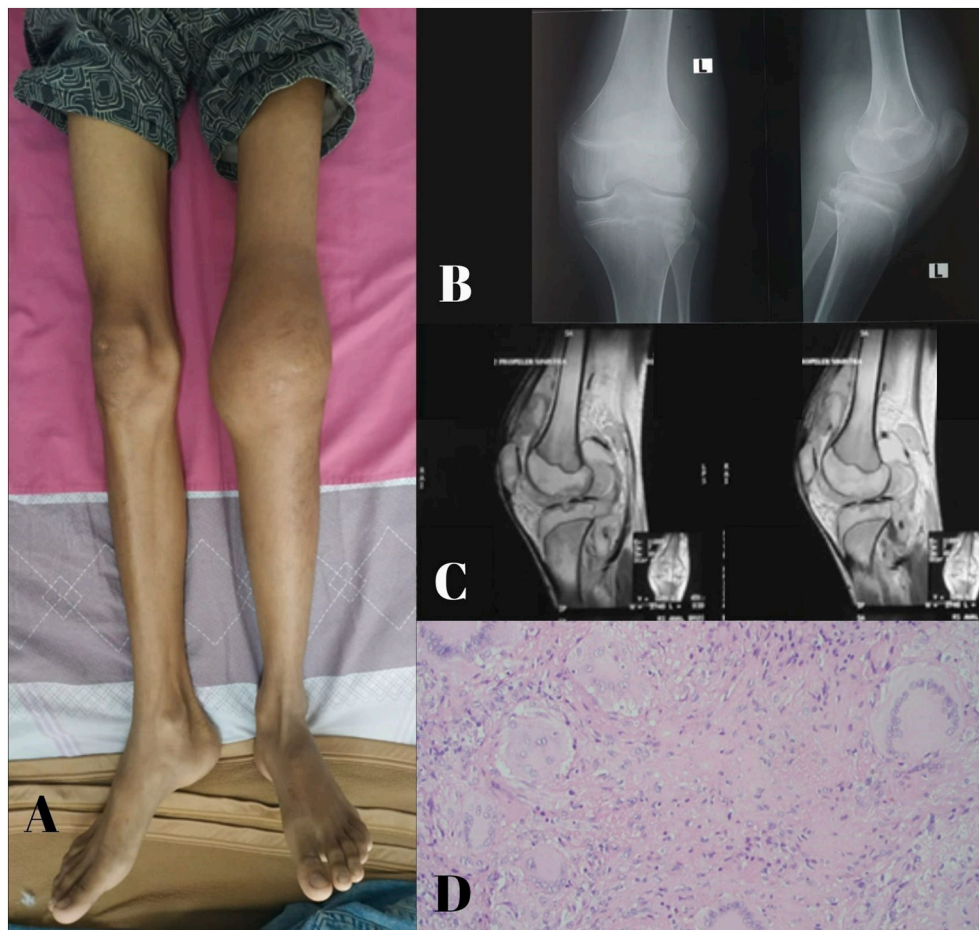


Fig. 2. Clinical appearance of the left knee (A); plain X-ray (B); MRI (C); and Histopathology result (D) of the second patient.

consisting of isoniazid, rifampin, pyrazinamide, and ethambutol, to prevent further tissue destruction. During the first two weeks, after taking the regimen, the patient felt the mass got smaller. After that, the patient underwent synovectomy (Fig. 3A) and debridement (Fig. 3B) of the left knee by the orthopaedic surgeon. Then, the patient continued the anti-tuberculosis drug regimen for 12 months. Four months after the surgery, the patient was free of pain and could perform full weight-bearing without assistance. At follow-up 24 months later (Fig. 3C), the patient regained acceptable ROM (0° – 90°) of the operated knee with no evidence of recurrence.

3. Discussion

According to Soeroso et al., Indonesia was the third country with the highest prevalence of tuberculosis [1]. Therefore, a patient presenting with chronic unilateral knee arthritis of unknown origin, TB gonitis should be included in the differential diagnosis to avoid misdiagnosing patients with this condition as having other inflammatory or neoplastic processes with similar clinico-radiological characteristics, such as PVNS.

Diagnose at an early stage of arthritis due to TB is essential to preserve the articular cartilage and joint space. Early diagnosis, specific and adequate treatment can be rewarding for maintaining proper joint function [11]. In the beginning, there is initial inflammatory synovitis with edema, clinically apparent as joint swelling, muscle spasm, and restricted movements [3]. An improper diagnosis may be due to atypical clinical presentation, wide use of antibiotics, the low specificity of diagnostic tools, and most of all, the clinician not prioritizing the possibility of tuberculous arthritis due to its rare incidence [3,7]. An analysis of 10 patients with tuberculous knee arthritis, diagnosed

preoperatively by clinical, radiologic examination, and polymerase chain reaction assays, found that only 2 (20%) were diagnosed correctly at admission. In contrast, the other eight (80%) were misdiagnosed preoperatively with rheumatic arthritis, gout arthritis, or osteoarthritis [7].

These patients present here were initially suspected of having diffuse PVNS because of their clinical manifestations, plain x-ray, and MRI features. Both tuberculous arthritis and PVNS in the knee joint of young, otherwise healthy-appearing individuals may present as monoarticular involvement, with painful swelling of extended duration (usually more than several months to years) and limited motion. The MRI manifestations of PVNS are joint effusion, a nodular proliferation of synovial membrane, bone marrow edema, and articular cartilage destruction. Clumps of hemosiderin deposits show a low signal intensity on T1 and T2 weighted images, which is the most indicative feature of PVNS. Imaging, especially MRI, plays a vital role in supporting the diagnosis of PVNS [4]. An open biopsy is increasingly used for establishing the working diagnosis of TB arthritis or PVNS of the knee. A definitive diagnosis of tuberculous infection relies on positive culture findings (80% positive rate); however, cultures require a long incubation period (up to 8 weeks) [3,6]. Thus, the histological finding of granuloma and caseating necrosis synovial biopsy of our patients is considered diagnostic.

The treatment goals of arthritis tuberculosis are eradicating infection, pain relief, and restoring joint function. The surgery role in treating osteoarticular TB is still somewhat controversial, varying throughout different regions of the world, both in terms of indications for surgery and the specific procedures recommended. As a general rule, surgery is reserved for particular indications to establish the diagnosis or treat

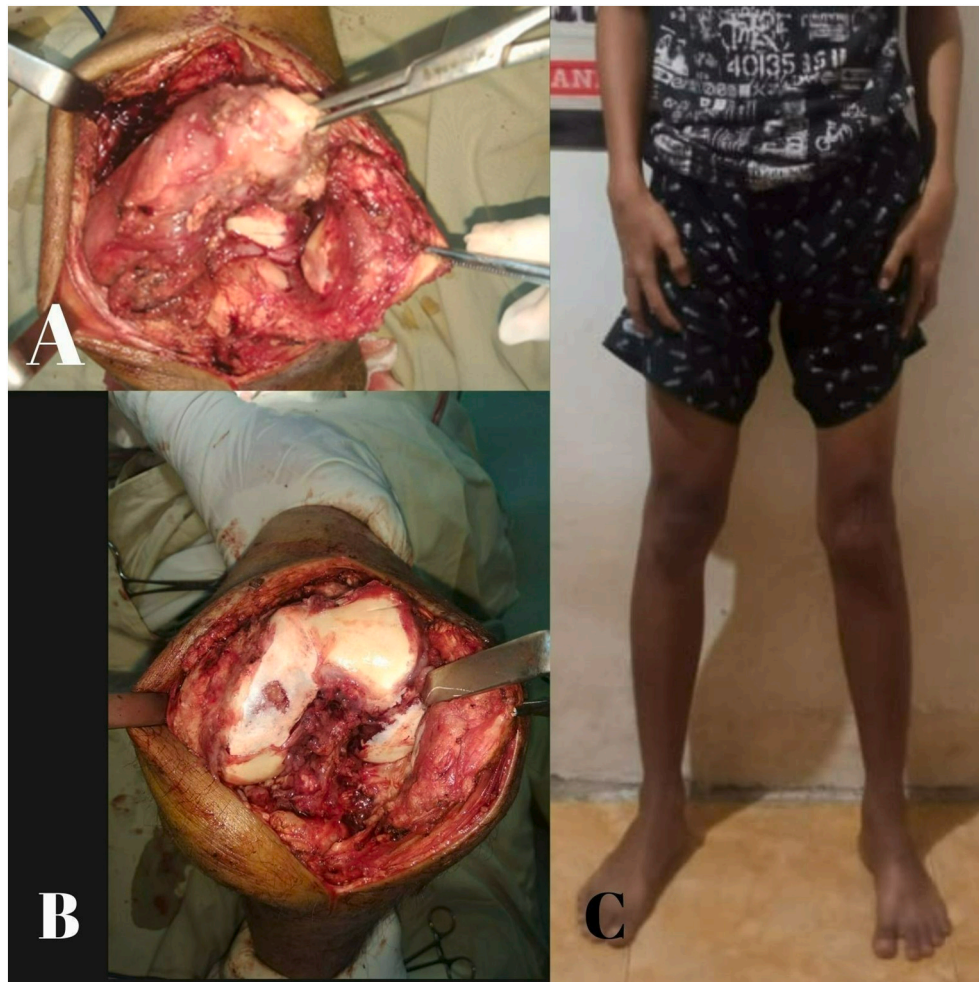

Fig. 3. Intraoperative gross appearance of the lesion in the knee joint (A); femoral cartilage appearance intraoperatively after synovectomy (B); clinical follow-up at 24 months after surgery (C).

complications of the disease process. The main indications for surgery are unresponsiveness after 4 to 5 months of the anti-tuberculous drug, severe joint destruction, joint deformity, large abscesses, neurological compromise, and painful joint ankylosis. The range of surgical procedures that could be carried out includes drainage of abscesses, synovectomy, excisional arthroplasty, arthrodesis for the joint, and joint replacement if the TB has remained inactive for at least ten years [6]. The second patient underwent surgery because the pathology report showed a tuberculous infection with clinical manifestation of the late stage of TB arthritis characterized by large painful mass, swelling, and stiffness in his left knee. Intraoperatively we found fibrosis of the knee joint capsule and destruction of the femoral cartilage. Surgical intervention was preferred to detect related pathology and achieve better functional outcomes, resulting in less pain and increasing range of motion of the knee joint.

4. Conclusion

In conclusion, the clinical and radiologic findings in TB gonitis and PVNS are occasionally similar. Therefore TB gonitis should be highly suspicious, especially in endemic areas. Histopathology results and mycobacterial culture need to determine the diagnosis.

Sources of funding

The research did not receive any specific grant from funding agencies

in the public, commercial, or not-for-profit sectors.

Ethical approval

All investigators ensure that the conduct of this study is in accordance with the ethical standards of their respective institutions, as laid down in the 1964 Declaration of Helsinki.

Consent

Written informed consent was obtained from the patient for publication of this case report and accompanying images. A copy of the written consent is available for review by the Editor-in-Chief of this journal on request.

Author contribution

MPJ contributed to perform the surgery, conceptualization, methodology, clinical data investigation, curation, and interpretation; IPP contributed to pathological data curation and interpretation; IN contributed to assist the surgery, clinical data interpretation; APA contributed to clinical data curation and interpretation. AFIW contributed to clinical data curation and interpretation; TS contributed to clinical data curation and interpretation. All authors: writing – original draft, review, editing, and approved the final manuscript for publishing.

Registration of research studies

Not applicable.

Guarantor

Muhammad Phetrus Johan, MD., PhD.

Provenance and peer review

Not commissioned, externally peer-reviewed.

Declaration of competing interest

The authors declare that there are no conflicts of interest regarding the publication of this article.

Acknowledgment

None.

References

- [1] N.N. Soeroso, F.R. Ananda, H. Rahmadhany, D.D. Putra, Tuberculosis of the knee: a pitfalls in clinical settings (a case report and literature review), *Int. J. Surg. Case Rep.* 71 (2020) 14–18, <https://doi.org/10.1016/j.ijscr.2020.04.090>.
- [2] H. Erdem, O. Baylan, I. Simsek, A. Dinc, S. Pay, M. Kocaoglu, Delayed diagnosis of tuberculous arthritis, *Jpn. J. Infect. Dis.* 58 (2005) 373–375.
- [3] A.N. Malaviya, P.P. Kotwal, Arthritis associated with tuberculosis, *Best Pract. Res. Clin. Rheumatol.* 17 (2003) 319–343, [https://doi.org/10.1016/s1521-6942\(02\)00126-2](https://doi.org/10.1016/s1521-6942(02)00126-2).
- [4] V.Y. Jo, C.D.M. Fletcher, WHO classification of soft tissue tumours: an update based on the 2013 (4th) edition, *Pathology* 46 (2014) 95–104, <https://doi.org/10.1097/PAT.000000000000050>.
- [5] E.B. Hoffman, J. Allin, J.A.B. Campbell, F.M. Leisegang, Tuberculosis of the knee, *Clin. Orthop. Relat. Res.* (2002) 100–106, <https://doi.org/10.1097/00003086-200205000-00014>.
- [6] I. Procopie, E.L. Popescu, V. Huplea, R.M. Pleșea, Ș.M. Ghelase, G.A. Stoica, R. F. Mureșan, V. Onțică, I.E. Pleșea, D.N. Anușca, Osteorarticular tuberculosis-brief review of clinical morphological and therapeutic profiles, *Curr. Heal. Sci. J.* 43 (2017) 171–190, <https://doi.org/10.12865/CHSJ.43.03.01>.
- [7] D.-H. Lee, D.-K. Lee, S.-H. Lee, J.-H. Park, C.-H. Kim, S.-B. Han, Tuberculous arthritis of the knee joint mimicking pigmented villonodular synovitis, *Knee Surg. Sports Traumatol. Arthrosc.* 20 (2012) 937–940, <https://doi.org/10.1007/s00167-011-1662-2>.
- [8] X.G. Cheng, Y.H. You, W. Liu, T. Zhao, H. Qu, MRI features of pigmented villonodular synovitis (PVNS), *Clin. Rheumatol.* 23 (2004) 31–34, <https://doi.org/10.1007/s10067-003-0827-x>.
- [9] L. Zhao, K. Zhou, Y. Hua, Y. Li, D. Mu, Multifocal pigmented villonodular synovitis in a child: a case report, *Medicine (Baltimore)* 95 (2016), e4572, <https://doi.org/10.1097/MD.0000000000004572>.
- [10] R.A. Agha, T. Franchi, C. Sohrabi, G. Mathew, A. Kerwan, The SCARE 2020 guideline: updating consensus surgical CAse REport (SCARE) guidelines, *Int. J. Surg.* 84 (2020) 226–230, <https://doi.org/10.1016/j.ijvsu.2020.10.034>.
- [11] C. Tseng, Tuberculosis arthritis: epidemiology, diagnosis, treatment, *Clin. Res. Foot Ankle.* 02 (2014), <https://doi.org/10.4172/2329-910X.1000131>.