

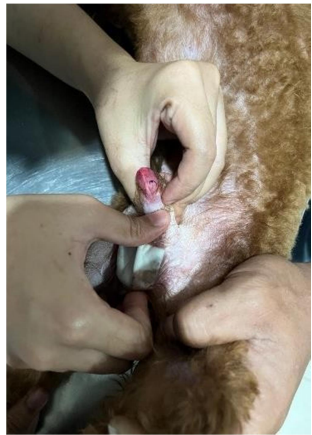

## DAFTAR PUSTAKA

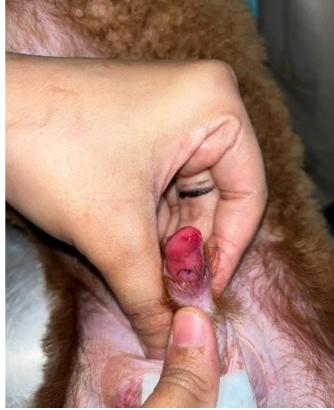- Anderson, Adriene. 2024. Rimadyl for Dogs (Carprofen). DogCancer.com, LLC. All Rights Reserved. DogCancer.com does not provide medical advice, diagnosis or treatment.
- Bani, R. F., Amalo, F. A., & Selan, Y. N. (2020). Gambaran anatomi dan histologi ginjal dan vesika urinaria pada musang luwak (*Paradoxurus hermaphroditus*) di Pulau Timor. *Jurnal Veteriner Nusantara*, 3(1), 74-84.
- Bojrab, M.J., Waldron, D.R. and Toombs, J.P., 2014. *Current techniques in small animal surgery*. CRC Press.
- Carr, J.G., Tobias, K.M. and Smith, L., 2014. Urethral prolapse in dogs: a retrospective study. *Veterinary surgery*, 43(5), pp.574-580.
- Evans, J., Hannoodee, M., & Wittler, M. (2019). Amoxicillin Clavulanate. Pp: 56.
- Grewal, M. K., Kudej, R. K., & Grace, M. (2024). Assessment of Combined Resection-Anastomosis and Urethropexy in Dogs with Urethral Prolapse. *Journal of the American Animal Hospital Association*, 60(5), 179-187.
- Griffon, D dan Hamaide A. 2016. *Complications in Small Animal Surgery*. Wiley Blackwell : USA.
- Healy, D., Rizkallal, C., Rossanese, M., McLarnon, P., Vallefucoco, R., Murgia, D., Ryan, T., Howes, C., Anderson, O., Charlesworth, T. and Cinti, F., 2024. Surgical treatment of canine urethral prolapse via urethropexy or resection and anastomosis. *Journal of Small Animal Practice*, 65(3), pp.206-213.
- Hermawan, I. P. (2023). Studi Kasus: Keberhasilan Terapi Pada Kasus Intoksikasi Kucing Kunkun. *Jurnal Veteriner dan Biomedis*, 1(1), 5-8.
- Jamilah, J. (2015). Evaluasi keberadaan gen *catp* terhadap resistensi kloramfenikol pada penderita demam tifoid. In *Prosiding Seminar Nasional Biologi* (Vol. 1, No. 1).
- Juliantari, N. K. A., Jayanti, P. D., & Suartha, I. N. (2023). Laporan Kasus: Ehrlichiosis pada Anjing Pomeranian Umur 4 Tahun. *Buletin Veteriner Udayana Volume*, 15(3), 471-482.

- Kim, D., Seo, M., Choi, G., Lee, S.K., Lee, S., Lee, W.J., Yun, S.H., Kwon, Y.S. and Jang, M., 2023. Cardiovascular and Respiratory Effects of Increased Intra-Abdominal Pressure with and without Dexmedetomidine in Anesthetized Dogs. *Veterinary Sciences*, 10(11), p.634.
- Langston, Cathy E. 2016. Urethral Prolapse in Dogs. Veterinary Surgery in Sarasota. University Park.
- Lopes, M. C. T., Brito, F. D., Silva, F. L., & Silva, C. D. (2012). Prolapse of mucosa urethral in dogs-case report.
- Mitze, S., Barrs, V.R., Beatty, J.A., Hobi, S. and Bęczkowski, P.M., 2022. Brachycephalic obstructive airway syndrome: much more than a surgical problem. *Veterinary Quarterly*, 42(1), pp.213-223.
- RABIDI, S., PAPAZOGLU, L., TSOBANIDOU, P. and HADDADIN, W., 2014. Management of severe penile swelling associated with urethropexy in an English bulldog. *Turkish Journal of Veterinary & Animal Sciences*, 38(1), pp.107-109.
- Santos, J. G., MARTINI, A., Monteiro, B. G., Schroder, D. C., Franco, G. D., MASCARENHAS, L., & SOUZA, R. (2018). Prolapso uretral em um cão da raça American Pit Bull. *Acta Scientiae Veterinariae*, 46(1), 248.
- Teixeira, L. G., de ATAIDE, M. W., Milech, V., Gavioli, F. B., Antunes, B. N., Abati, S. L. & Brun, M. V. (2017). Urethral prolapse corrected by microsurgery in a cat: a case report. *Journal of Veterinary Medical Science*, 79(12), 2023-2025.
- Teixeira, L.G., de ATAIDE, M.W., Milech, V., Gavioli, F.B., Antunes, B.N., Abati, S.L., Pinto Filho, S.T.L. and Brun, M.V., 2017. Urethral prolapse corrected by microsurgery in a cat: a case report. *Journal of Veterinary Medical Science*, 79(12), pp.2023-2025.
- Thahir, Z. and Saputri, H.N., 2023. Pola penggunaan obat perkemihan cystitis pada rawat inap kucing di Makassar Pet Clinic pada tahun 2021. *Jurnal Kesehatan Yamasi Makassar*, 7(1), pp.28-38.

## LAMPIRAN

### Monitoring Pasien

Hari	Keterangan
<b>Hari ke-1</b> 	<p>Waktu : 16 Agustus 2024 Suhu : 38,7 °C</p> <p>Pengobatan : <i>Amoxicillin</i> (oral) 1 ml q12h, <i>Rymadil</i> (oral) 1/4 tablet q12h, dan luka jahitan kastrasi diberikan salep <i>chloramphenicol</i> 2%.</p> <p>Kondisi : Suhu tubuh normal pasca operasi, jahitan uretra dalam keadaan baik, sudah pee, nafsu makan baik, sudah bisa jalan</p>
<b>Hari ke-2</b> 	<p>Waktu : 17 Agustus 2024 Suhu : 38,5 °C</p> <p>Pengobatan : <i>Amoxicillin</i> (oral) 1 ml q12h, <i>Rymadil</i> (oral) 1/4 tablet q12h, dan luka jahitan kastrasi diberikan salep <i>chloramphenicol</i> 2%.</p> <p>Kondisi : Suhu tubuh normal, jahitan rapat tidak ada seroma.</p>
<b>Hari ke-3</b>	<p>Waktu : 18 Agustus 2024 Suhu : 38,5 °C</p> <p>Pengobatan : <i>Amoxicillin</i> (oral) 1 ml q12h, <i>Rymadil</i> (oral) 1/4 tablet q12h, dan luka jahitan kastrasi diberikan salep <i>chloramphenicol</i> 2%.</p>



Kondisi : Suhu tubuh normal, jahitan rapat  
tidak ada seroma, sudah pee dan poop.