

## DAFTAR PUSTAKA

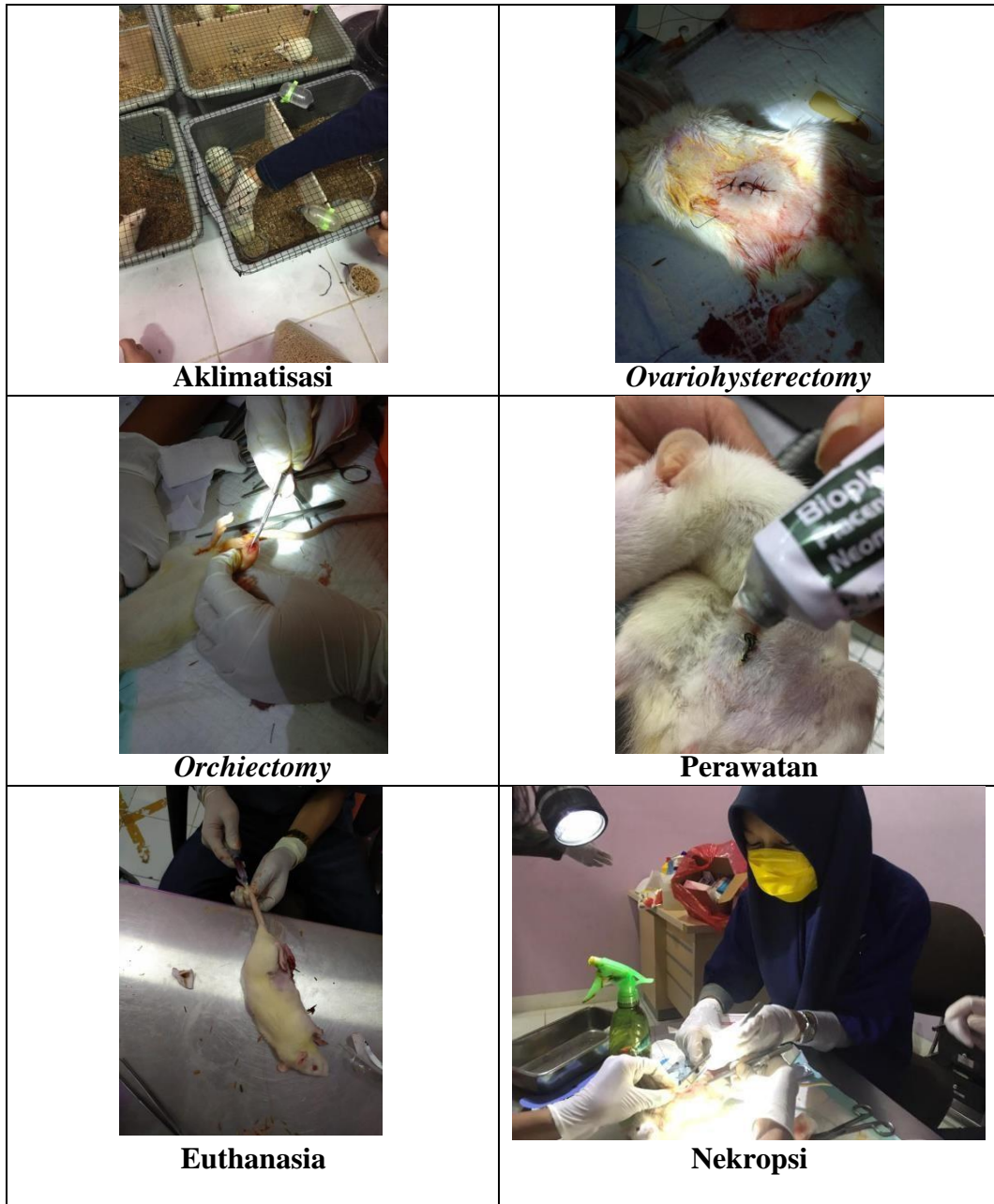
- Amiruddin, S., Zuraidawati, R. Desky, T.N. Siregar, A. Sayuti dan A. Harris. 2015. Pengaruh Pemberian Getah Buah Papaya (*Caica papaya L.*) Dan Povidone Iodine Terhadap Kesembuhan Luka Kastrasi Pada Kucing (*Felis domestica*) Jantan. *Jurnal Medika Veterinaria*. 9(1): 44-8.
- Antus, B., Hamar, P., Kokeny, G., Szollosi, Z., Mucsi, I., Nemes, Z., & Rosivall, L. 2003. Estradiol is nephroprotective in the rat remnant kidney. *Nephrology Dialysis Transplantation*, 18(1), 54-61.
- Aspinall, V dan M. Cappello. 2009. *Introduction To Veterinary Anatomy and Physiology textbook Second Edition*. China: Elsevier.
- Asrat, M., dan Melkamu, S. 2007. Review on Ovariohysterectomy: Surgical approach, Post operative Complications and their Management in Bitches. *Contraception*, 8.
- Brown, C. 2008. Intra-abdominal castration in the rat. *Lab animal*, 37(2), 73-74.
- Chakrabarti, S., Syme, H. M., Brown, C. A., & Elliott, J. 2013. Histomorphometry of feline chronic kidney disease and correlation with markers of renal dysfunction. *Veterinary pathology*, 50(1), 147-155.
- Christy, N.P. dan J. C. Shaver. 1974. Estrogens and The Kidney. *Kidney International*. 6 (1974): 366-376.
- Coville, T. dan J. M. Bassert. 2016. *Clinical Anatomy and Physiology for Veterinary Technicians : 3<sup>rd</sup> Edition*. Canada : Elsevier.
- Elliott, J., Rawlings, J. M., Markwell, P. J., & Barber, P. J. 2000. Survival of cats with naturally occurring chronic renal failure: effect of dietary management. *Journal of Small Animal Practice*, 41(6), 235-242.
- Ellison, K. E., Ingelfinger, J. R., Pivor, M., & Dzau, V. J. (1989). Androgen regulation of rat renal angiotensinogen messenger RNA expression. *The Journal of clinical investigation*, 83(6), 1941-1945
- Fogo, A. B. 2000. Glomerular hypertension, abnormal glomerular growth, and progression of renal diseases. *Kidney international*, 57 (75), S15-21.
- Ghufron, M. 2001. Gambaran Struktur Histologi Hepar dan Ren Mencit Setelah Pemberian Perlakuan Infus Akar Rimpang Jahe (*Zingiber officinale*) dengan Dosis Bertingkat. *Jurnal Kedokteran Yarsi*. Vol.9, No.1
- Greene, J. P., Lefebvre, S. L., Wang, M., Yang, M., Lund, E. M., & Polzin, D. J. 2014. Risk factors associated with the development of chronic kidney disease in cats evaluated at primary care veterinary hospitals. *Journal of the American Veterinary Medical Association*, 244(3), 320-327
- Haas, E., Bhattacharya, I., Brailoiu, E., Damjanovic, M., Brailoiu, G. C., Gao, X., ... & Barton, M. 2009. Regulatory role of G protein-coupled estrogen receptor for vascular function and obesity. *Circulation research*, 104(3), 288-291.

- Harmila, D., Rais dan Fadryani. 2016. Analisis Keaktifan Mahasiswa Jurusan Matematika Fakultas Mipa Universitas Tadulako Dengan Metode Mann Whitney. *Jurnal Ilmiah Matematika Dan Terapan*. 12 (2) : 104-114.
- Johnson-Delaney, C. 2002. Ovariohysterectomy in a Rat. *Exotic*. 4(4): 17-21.
- Karaduman, A. B., Kilic, V., Atli-Eklioglu, O., Baysal, M., Aydogan-Kılıc, G., Ucarcan, S., dan Ilgin, S. 2019. Reproductive toxic effects and possible mechanisms of zonisamide in male rats. *Human & experimental toxicology*. 38(12), 1384-1396.
- Katherine, M., dan Linda, R. (2013). Contraception and Fertility Control in Dogs and Cats. *Portland: Alliance for Conception in Cats and Dogs*. Hal, 19-24.
- Khairiyah, K. 2011. Zoonosis dan Upaya Pencegahannya (Kasus Sumatera Utara). *Jurnal Penelitian dan Pengembangan Pertanian*, 30(3), 117-124.
- Kustritz, Root M. V. 2012. Effects of surgical sterilization on canine and feline health and on society. *Reproduction in domestic animals*, 47(4), 214-222.
- Max, A., Jurka, P., Dobrzynski, A., dan Rijsselaere, T. 2014. Non-surgical contraception in female dogs and cats. *Acta Scientiarum Polonorum. Zootechnica*, 13(1). 3-18
- Maynard, R. L. dan N. Downes. 2019. *Anatomy and Histology of the Laboratory Rat in Toxicology and Biomedical Research*. India : Elsevier.
- Miller, L., & Zawistowski, S. (Eds.). 2012. *Shelter medicine for veterinarians and staff*. John Wiley & Sons.
- Office International des Epizooties (OIE). 2019. Stray Dog Population Control. OIE Terrestrial Animal Health Code, Chapter 7.7.6. Paris (France): Office International des Epizooties. p: 1-12.
- Olson, M. E. dan J. Bruce. 1986. Ovariectomy, Ovariohysterectomy And Orchidectomy In Rodents and Rabbits. *Can Vet J*. 27 (12) : 523-527.
- O'Malley, B. 2005. *Clinical anatomy and physiology of exotic species*. Germany :Elsevier
- Purnamasari, P., Purnawati, R. D., & Susilaningih, N. 2018. *Pengaruh Ekstrak Daun Sukun (Artocarpus Altilis) dan Madu Terhadap Gambaran Mikroskopis Ginjal Tikus Wistar yang Diinduksi Dietilnitrosamin* (Doctoral dissertation, Faculty of Medicine).
- Quesenberry, K. E. dan J. W. Carpenter. 2012. *Ferrets, Rabbits, and Rodents: Clinical Medicine And Surgery. Third Edition*. USA :Elsevier.
- Rejeki, P.S., E. A. C. Putri dan R. E. Prasetya. 2018. *Ovariectomi Pada Tikus dan Mencit*. Surabaya: Pusat Penerbitan dan Percetakan Universitas Airlangga (AUP).
- Reuter, J. D. dan M.A. Suckow. 2006. *Laboratory Animal Medicine and Management*. New York : International Veterinary Information Service.
- Richardson, C., dan Flecknell, P. 2006. Routine neutering of rabbits and rodents. *In Practice*, 28(2), 70-79.
- Schudamore, Cheryl L. 2014. *A Practical Guide to The Histology of The Mouse*. Wiley Blackwell: UK.

- Selvi, N. Z., Riauwaty, M., & Syawal, H. 2016. Histopathology Kidney of Pangasius hypophthalmus That Are Immersed In Curcumin and Were Infected by Aeromonas hydrophila. *Jurnal Online Mahasiswa*, 3(2), 1-11
- Sharp, P.E dan M.C. La regina. 1998. *The laboratory Rat*. US: CRC Press.
- Shortliffe, L. M. D., Ye, Y., Behr, B., dan Wang, B. 2014. Testosteron changes bladder and kidney structure in juvenile male rats. *The Journal of urology*, 191(6), 1913-1919.
- Siahaan, A. V., & Chan, A. 2018. Efektivitas Sediaan Gel dari Ekstrak Etanol Daun Pegagan (*Centella asiatica* L) dan Daun Pepaya (*Carica papaya* L. *Jurnal Dunia Farmasi*, 2(2), 59-69.
- Suparman, E., dan Suparman, E. (2014). Peran estrogen dan progesteron terhadap kanker payudara. *JURNAL BIOMEDIK: JBM*, 6(3).141-148
- Treuting, P. M., S. M. Dintzis dan K. S. Montine. 2018. *Comparative Anatomy And Histology A Mouse, Rat, And Human Atlas Second Edition*. India : Elsevier.
- Vasetska, A. I., dan Mass, A. A. 2017. The use of hormon containing contraceptive drugs and their effects on the reproductive system of dogs and cats. *Journal for veterinary medicine, biotechnology and biosafety*, 3(1), 21-25.
- Yanes, L. L., Sartori-Valinotti, J. C., dan Reckelhoff, J. F. 2008. Sex steroids and renal disease: lessons from animal studies. *Hypertension*, 51(4), 976-981.
- Yuniarti, WM, Ira SY dan Nusdianto T. 2009. Gambaran Histopatologik Ginjal Tikus Putih (*Rattus Norvegicus*) Pasca Ovariohisterektomi Dengan Suplemen Kalsium Karbonat Dosis Tinggi. *J. Penliti. Med. Eksakta*. 8(1); 31-38.

## LAMPIRAN

### Lampiran 1. Dokumentasi Kegiatan Penelitian





**Pemotongan organ**



**Fiksasi**



**Dehidrasi**



**Clearing**



**Infiltrasi**



**Embedding**



**Pemotongan**



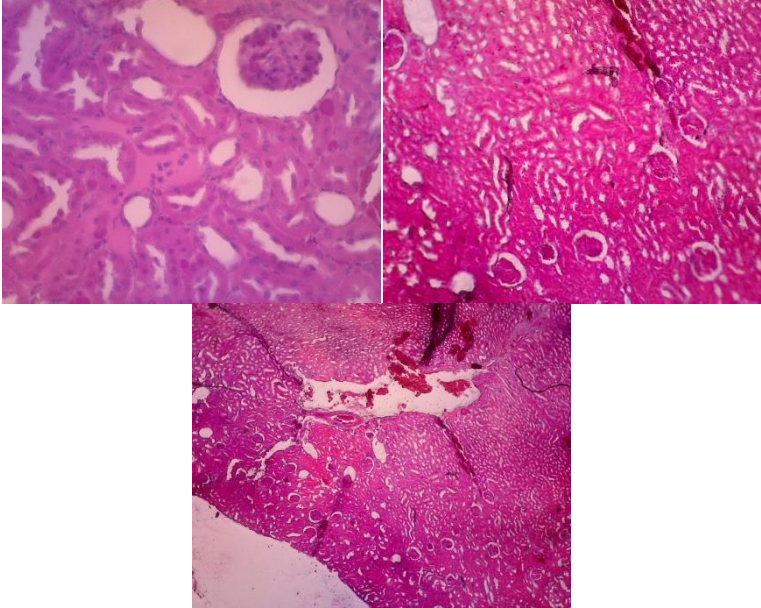
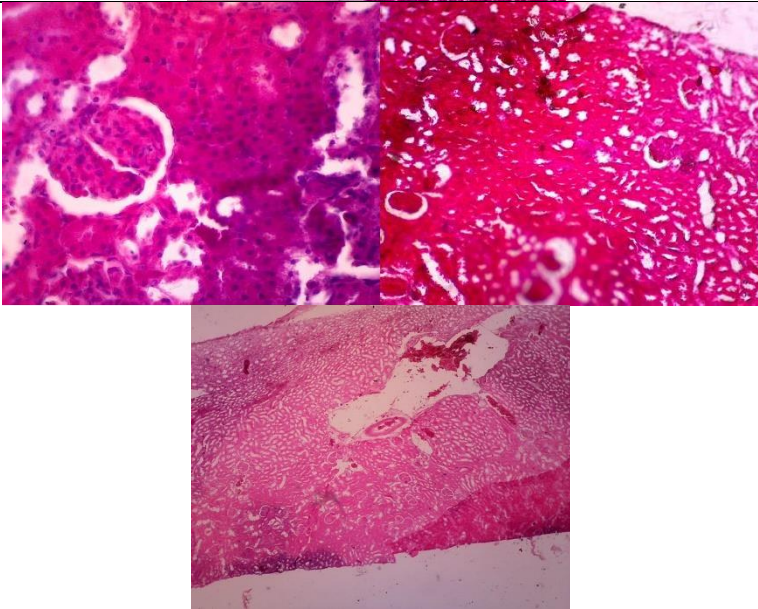
**Pewarnaan**

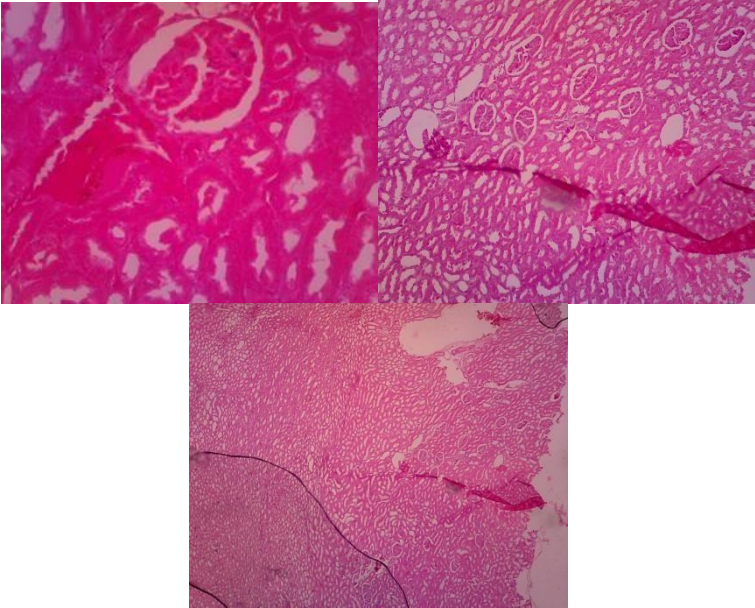
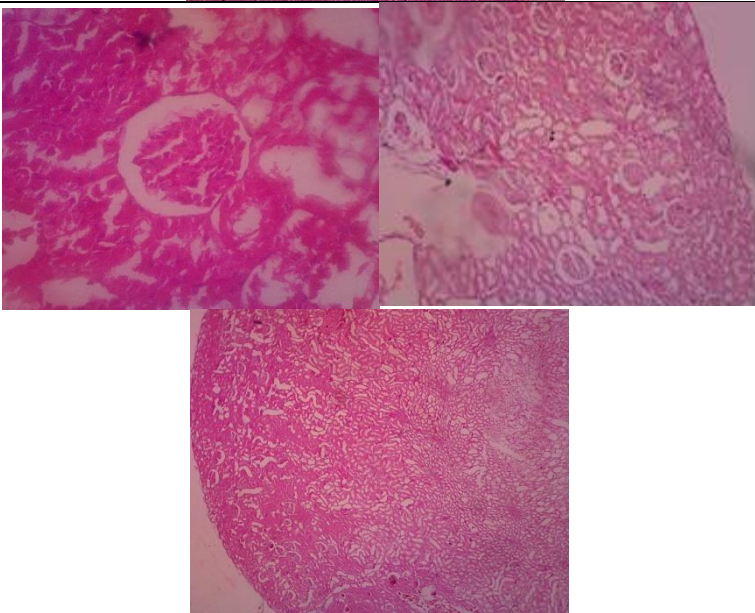


Lampiran 2. Hasil Pengamatan Histopatologi Ginjal Tikus Putih

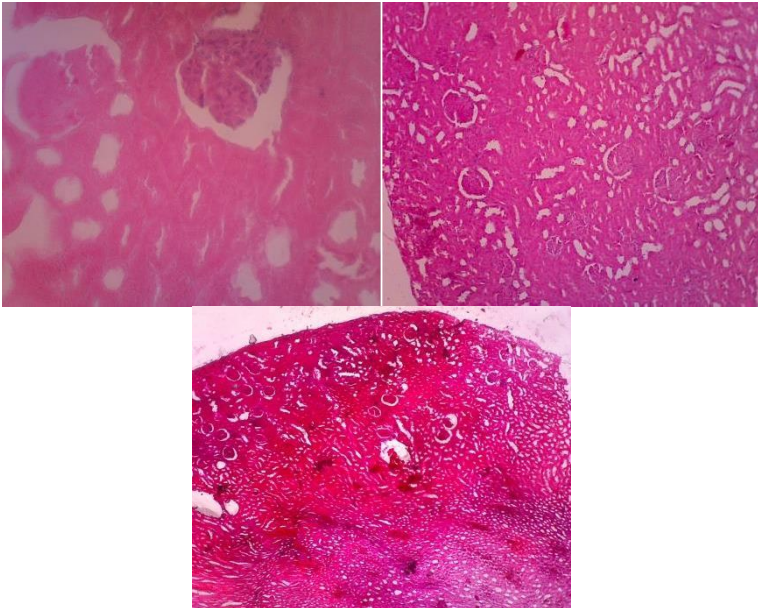
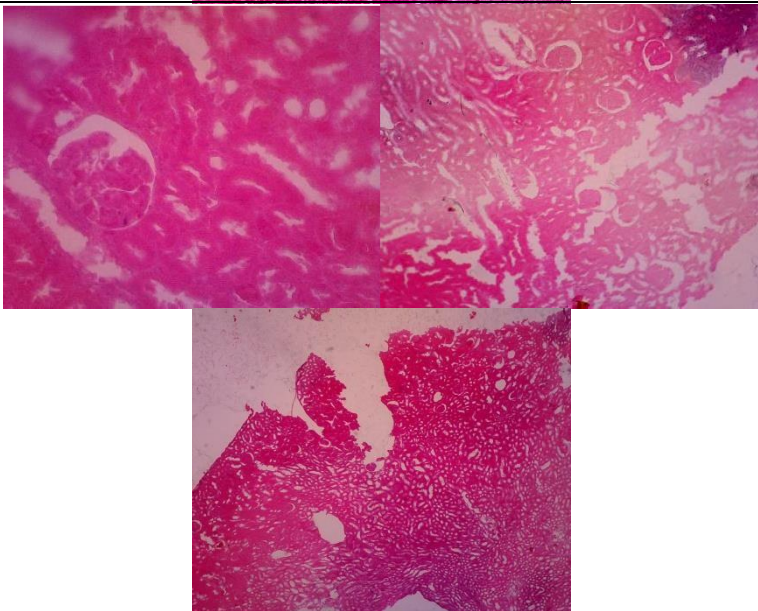
Kode	Gambar	Berat (g)	Skor
P01.1		0,78	-

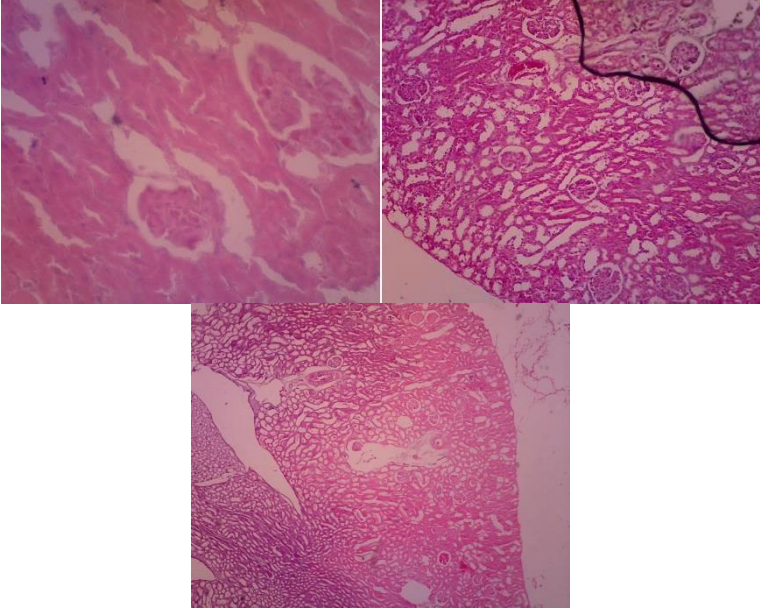
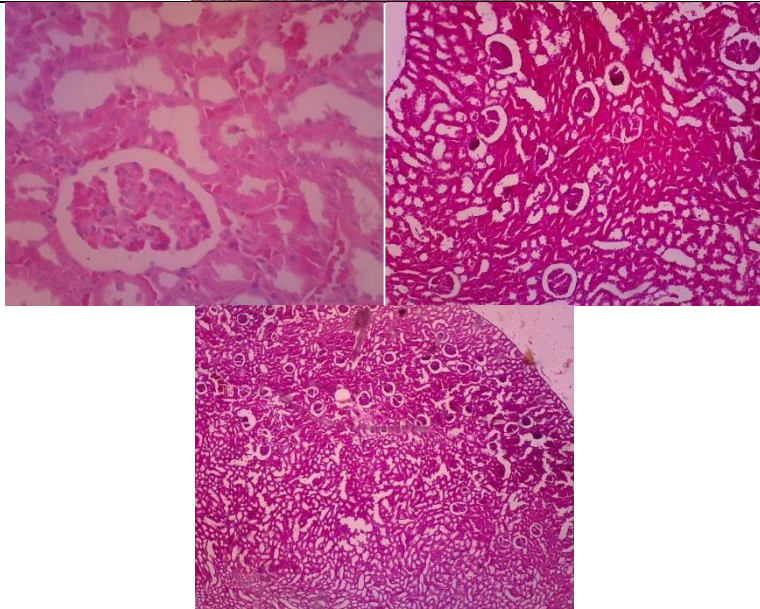


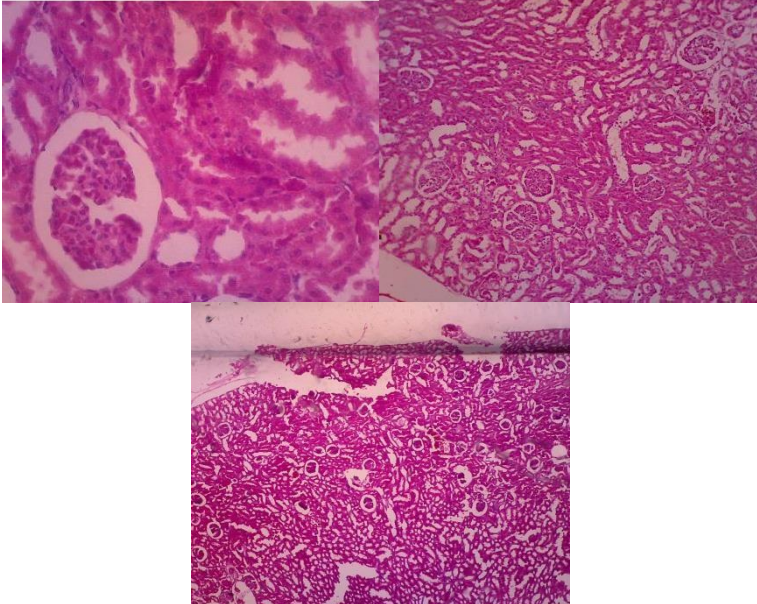
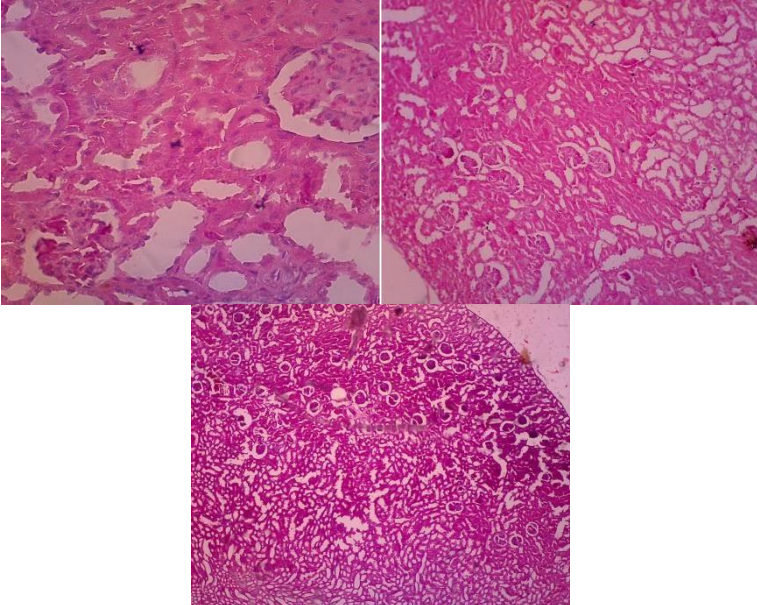
P01.2		0,71	-
P01.3		0,74	-

P01.4		0,74	-
P01.5		0,70	-

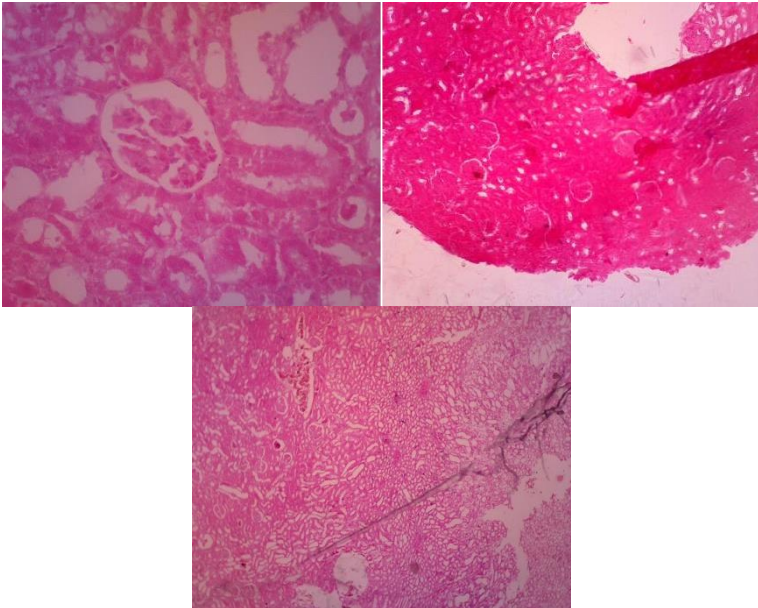
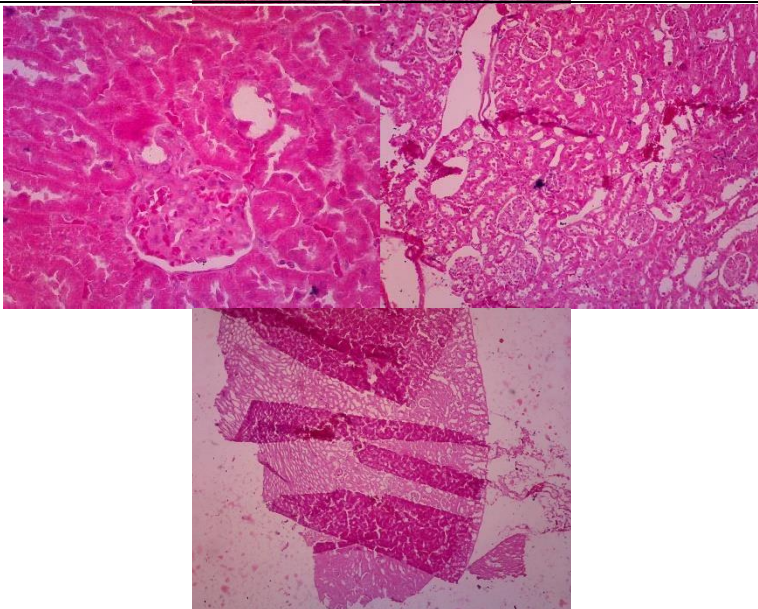


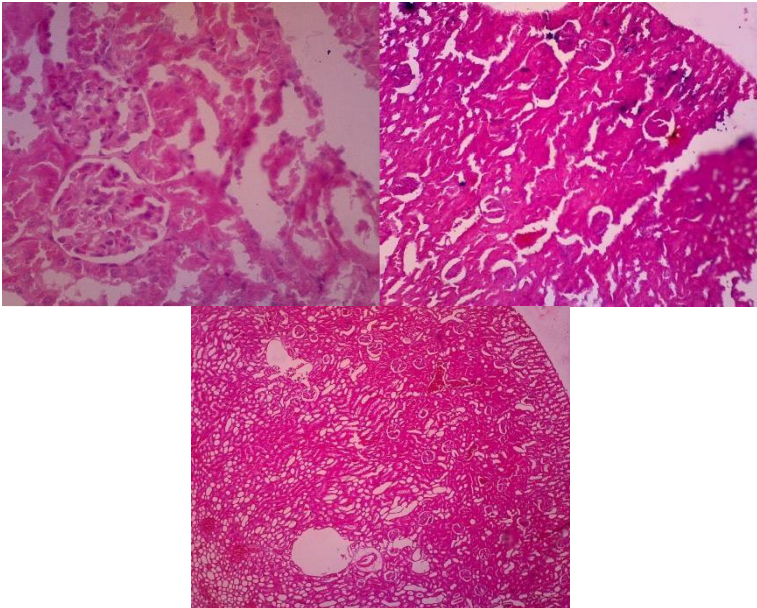
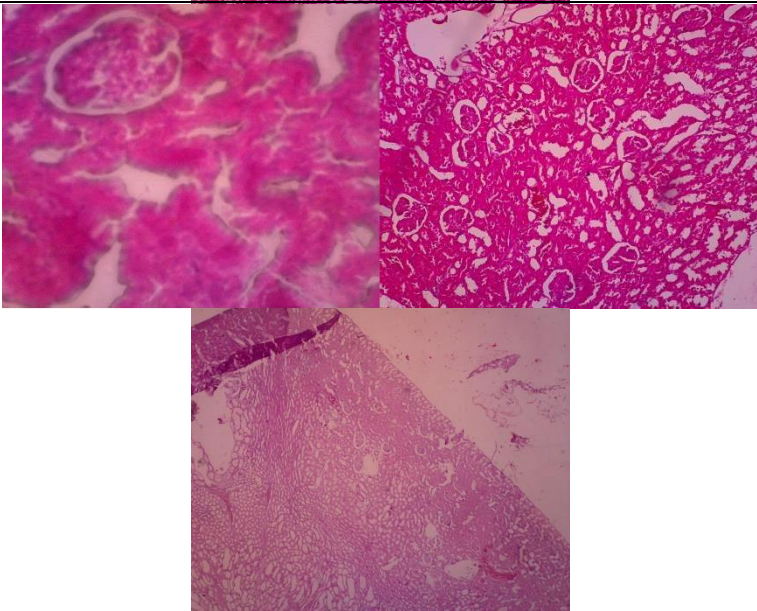
P01.6		0,76	+
P01+.1		0,75	+

P01+.2		0,70	-
P01+.3		0,65	-

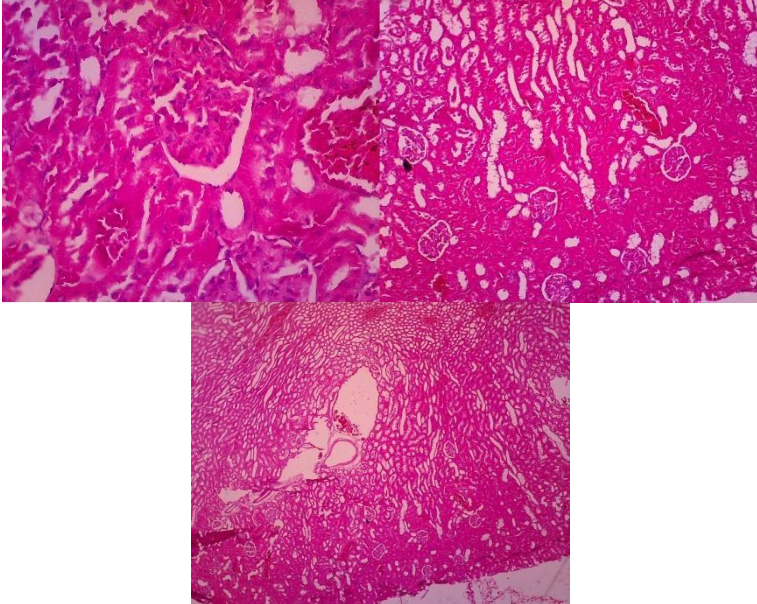
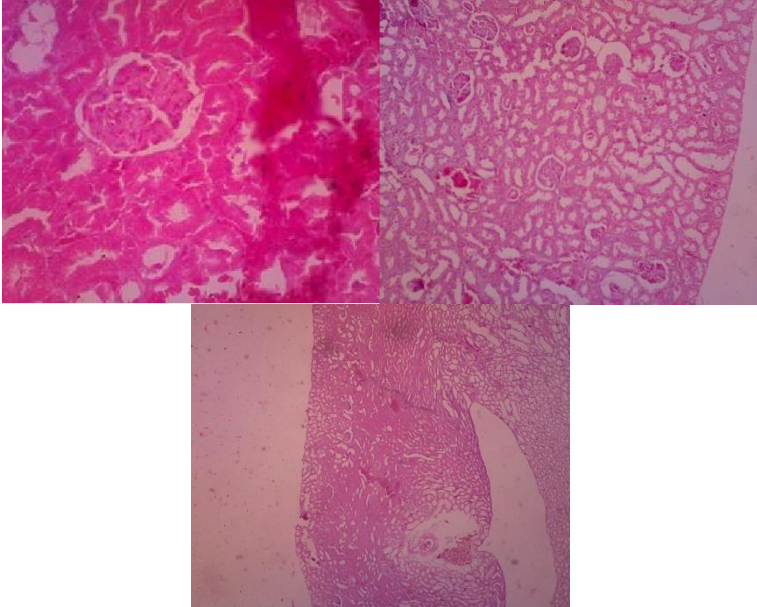
P01+.4		0,76	+
P01+.5		0,68	+

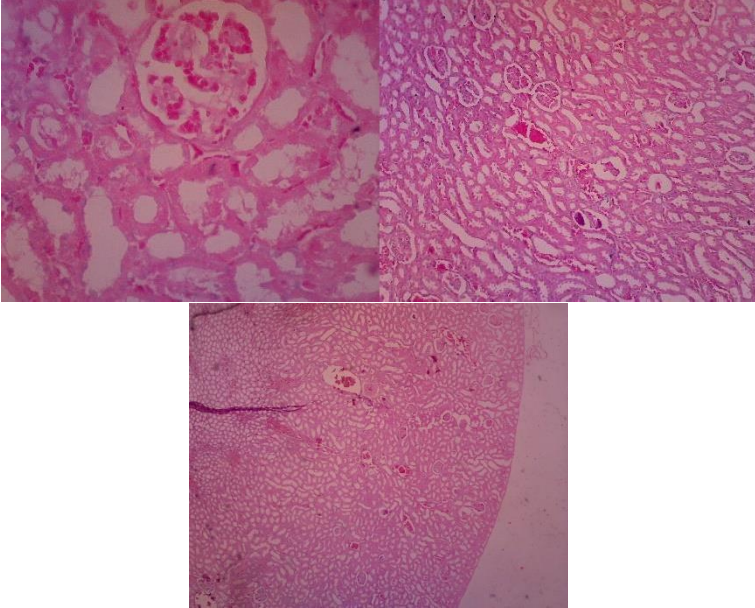
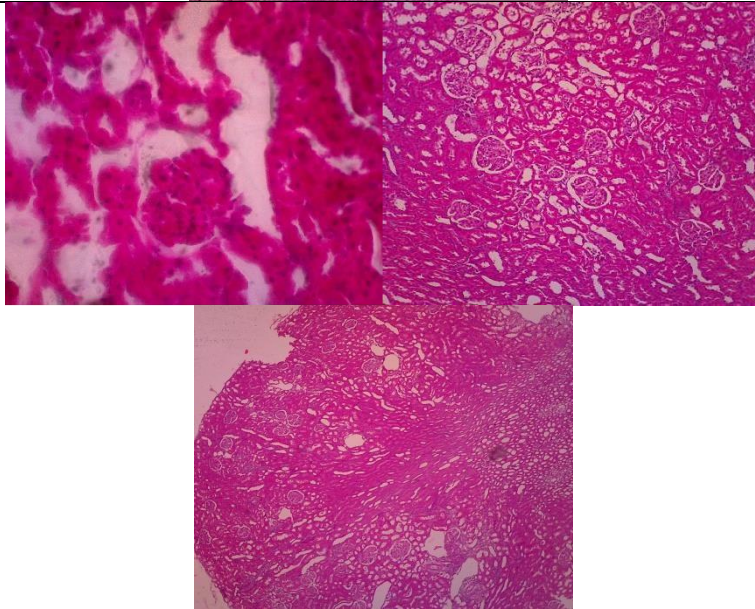


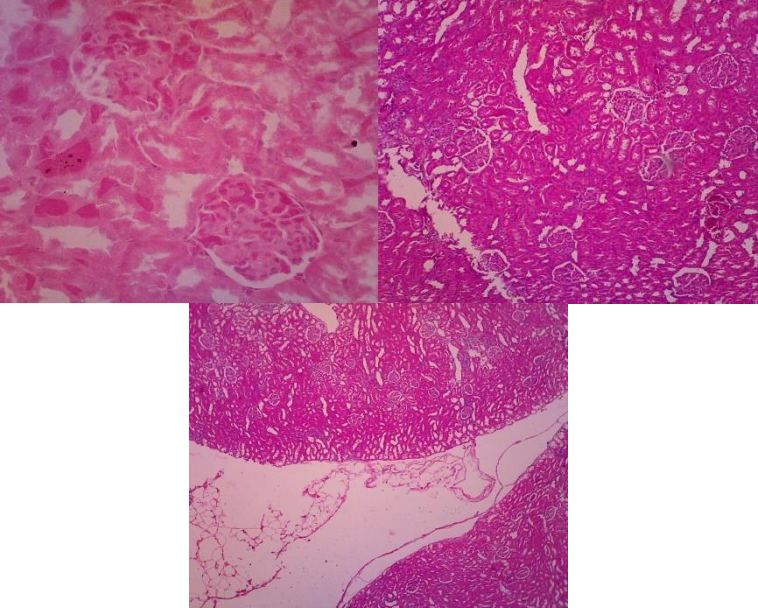
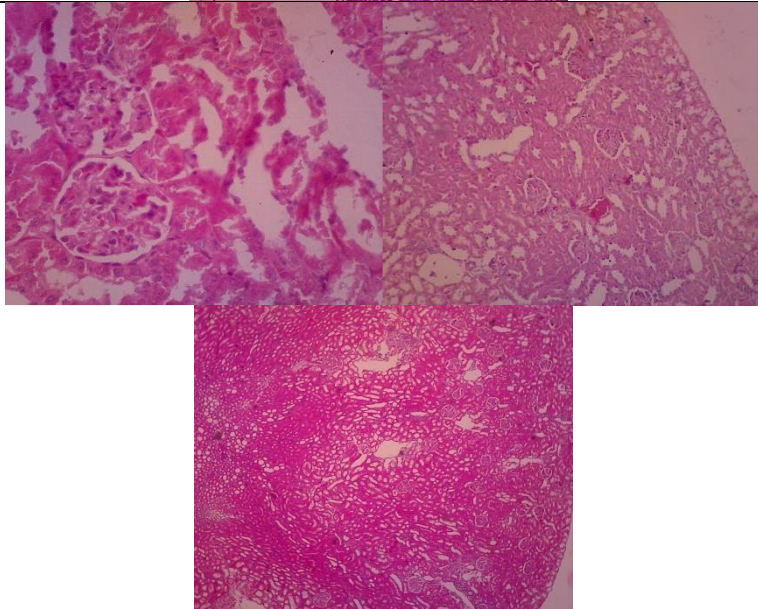
P01+.6		0,65	+
P1.1		1,05	++

P1.2		1,09	++
P1.3		0,89	++

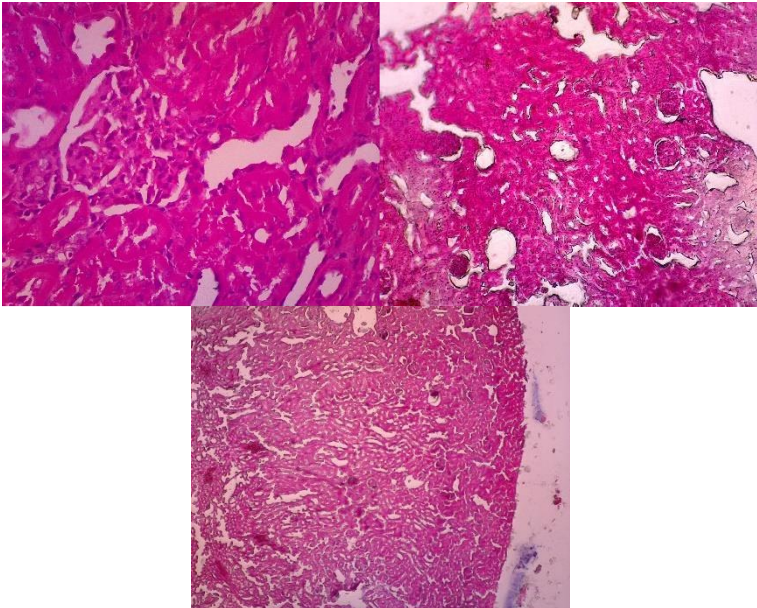
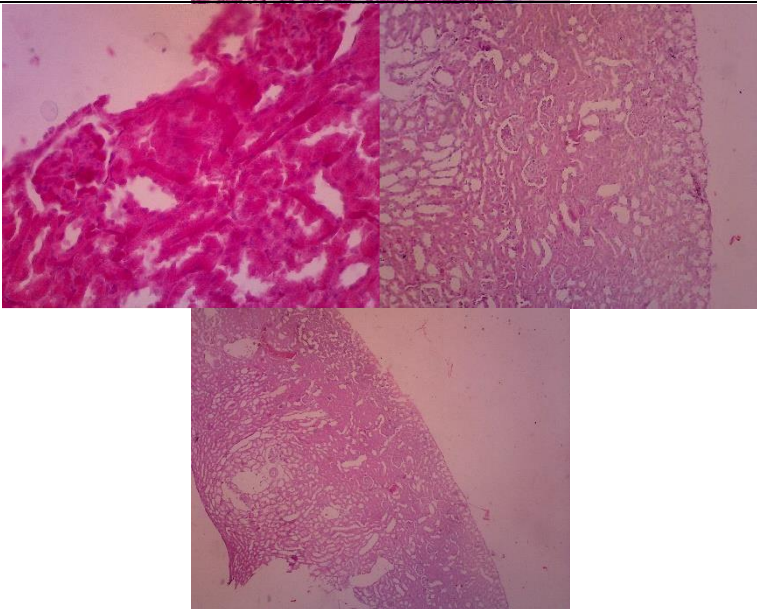


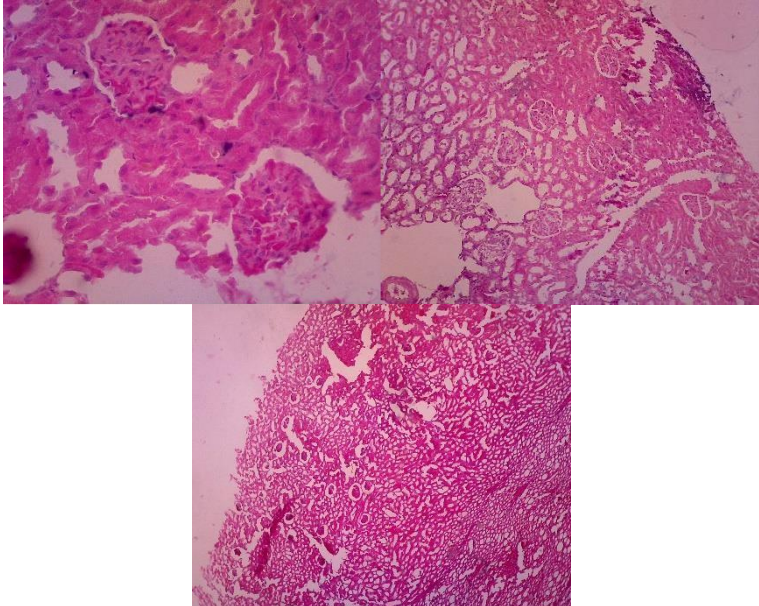
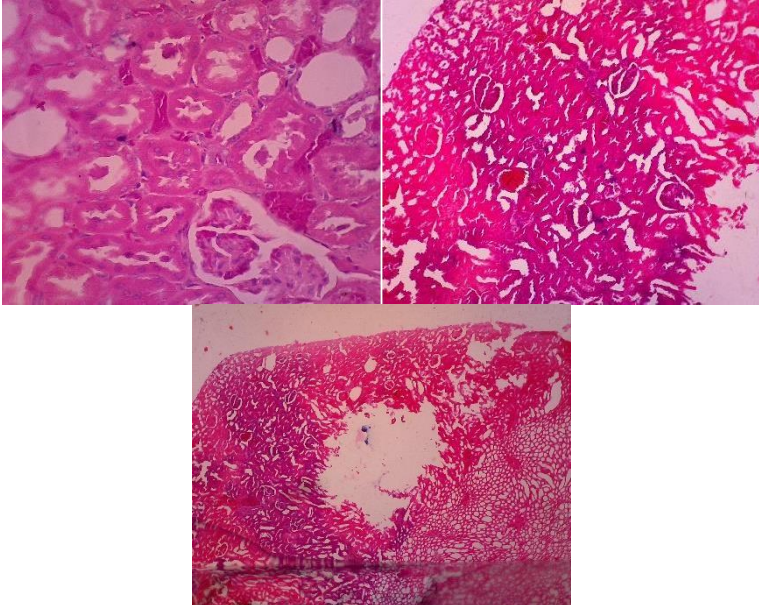
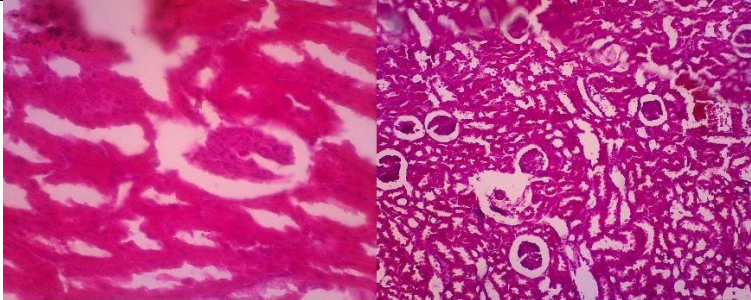
P1.4		1,05	++
P1.5		1,10	+

P1.6		0,91	+
P1+.1		0,70	++

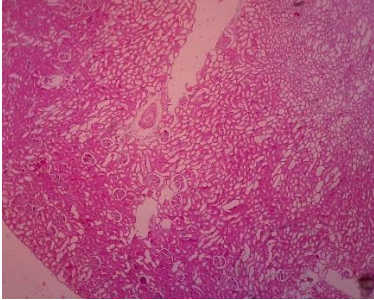
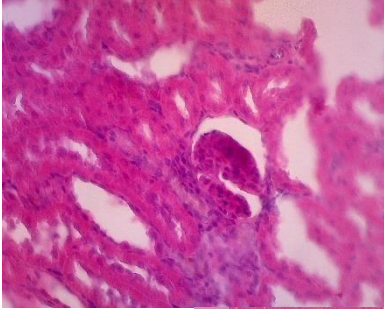
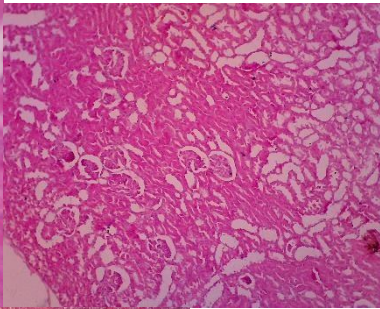
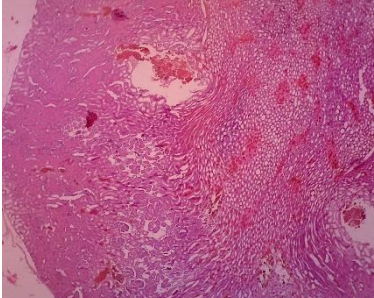

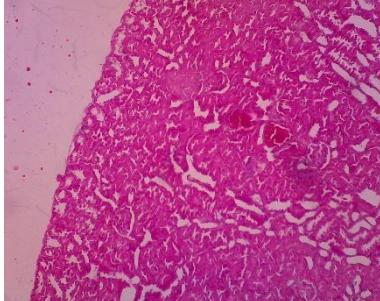
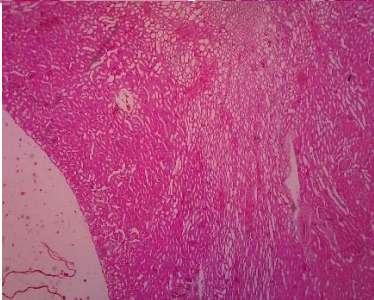
P1+.2		0,79	++
P1+.3		0,91	++

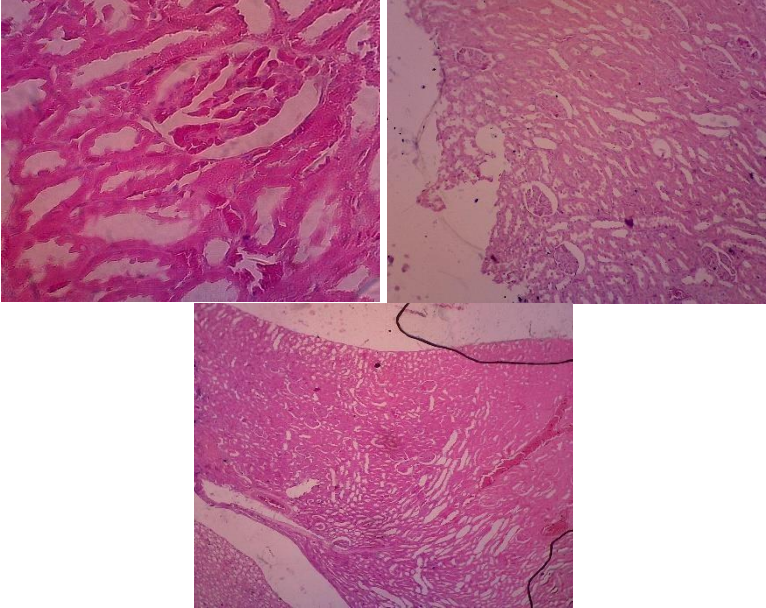
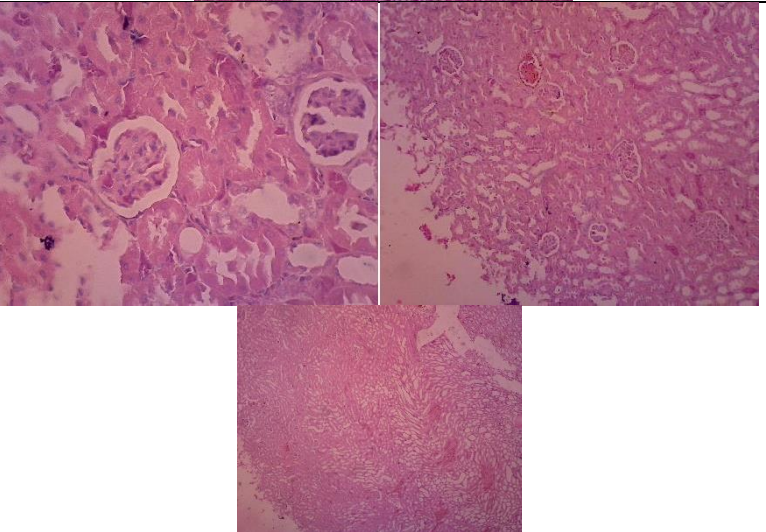
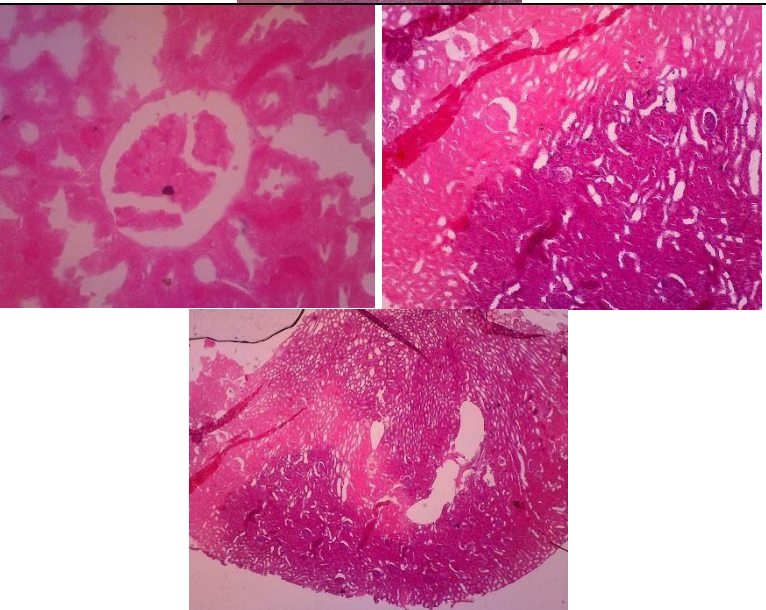


P1+.4	 <p>Two sets of histological images for P1+.4. The top set shows two panels: the left panel is a high-magnification view of a dense cellular area with some glandular structures, and the right panel is a lower-magnification view showing a similar dense cellular structure with more visible glandular elements. The bottom set shows a single panel of a lower-magnification view of a dense cellular structure, possibly representing a different section or a different magnification of the same tissue.</p>	0,69	++
P1+.5	 <p>Two sets of histological images for P1+.5. The top set shows two panels: the left panel is a high-magnification view of a dense cellular area, and the right panel is a lower-magnification view showing a similar dense cellular structure with more visible glandular elements. The bottom set shows a single panel of a lower-magnification view of a dense cellular structure, possibly representing a different section or a different magnification of the same tissue.</p>	0,77	++

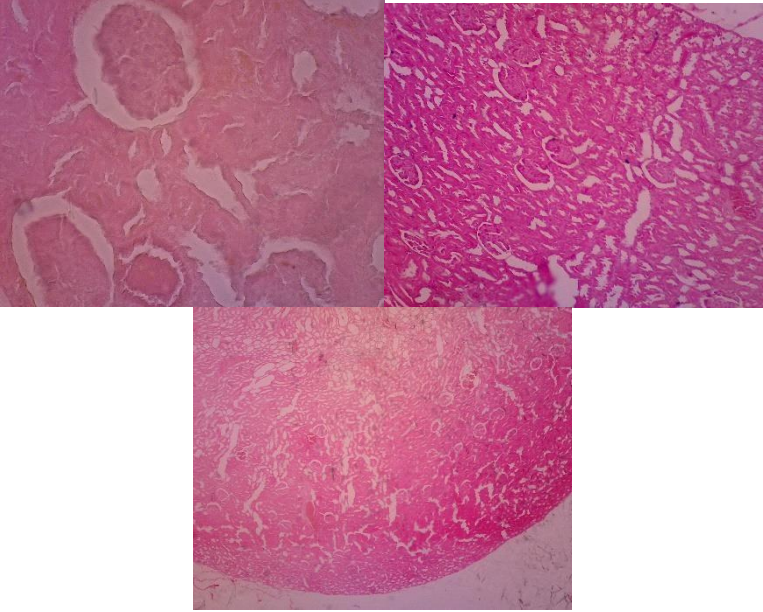
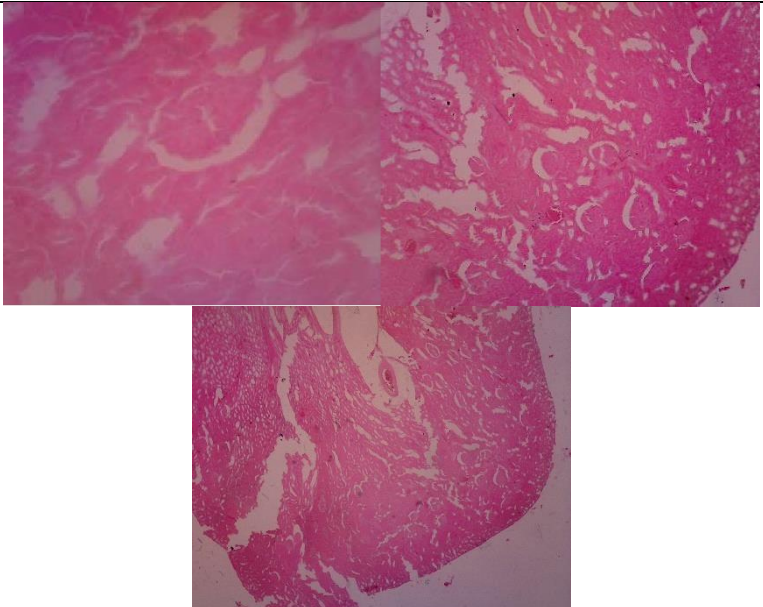
P1+.6		0,88	++
P02.1		0,78	-
P02.2		0,85	-

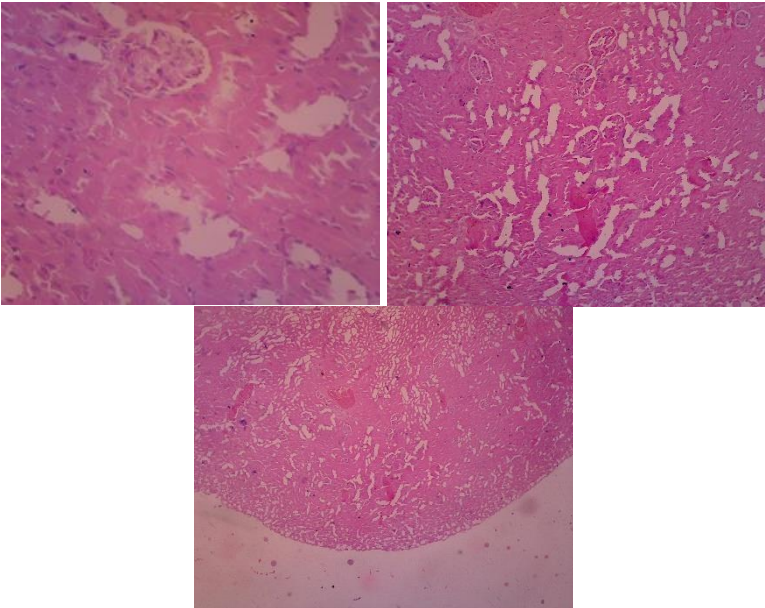
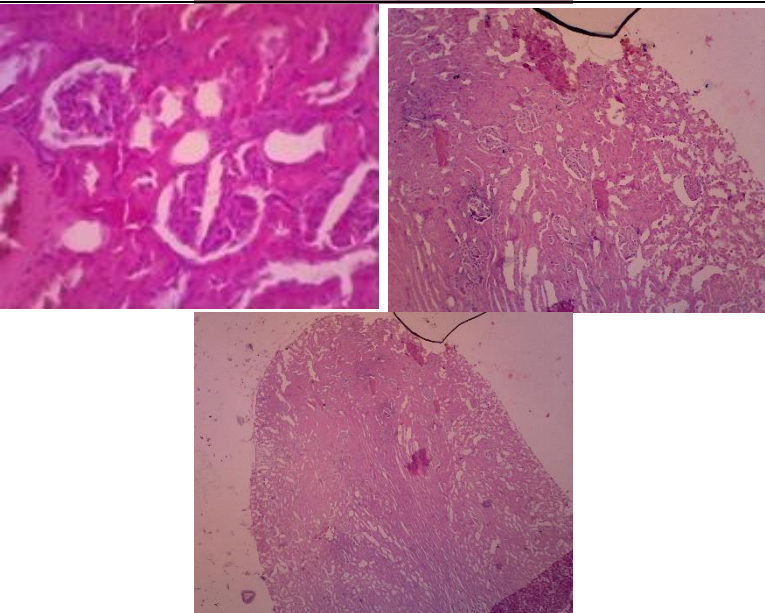


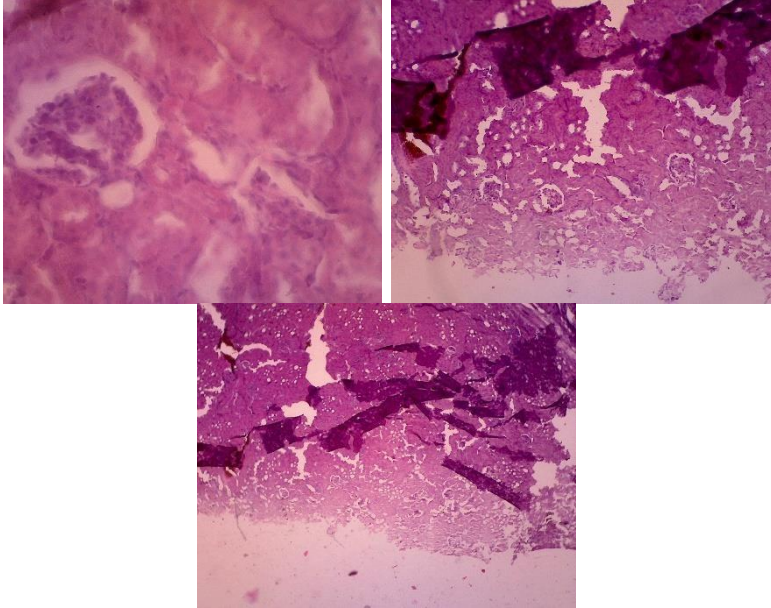
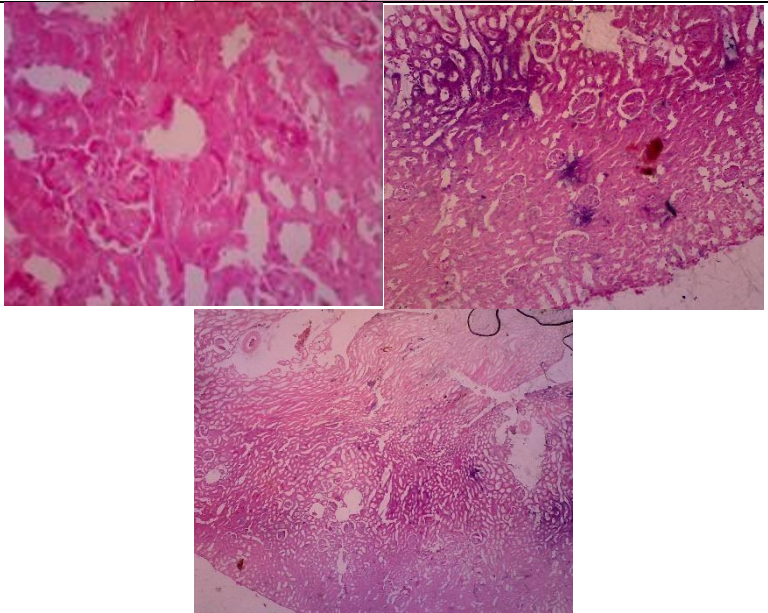
				
P02.3	  		0,83	-
P02.4	  		0,77	+

P02.5		0,88	+
P02.6		0,82	-
P02+.1		0,79	-

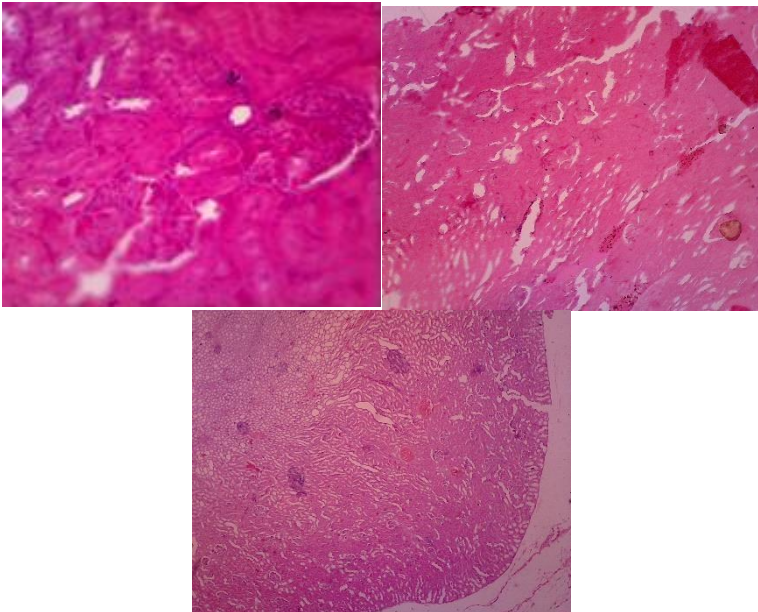
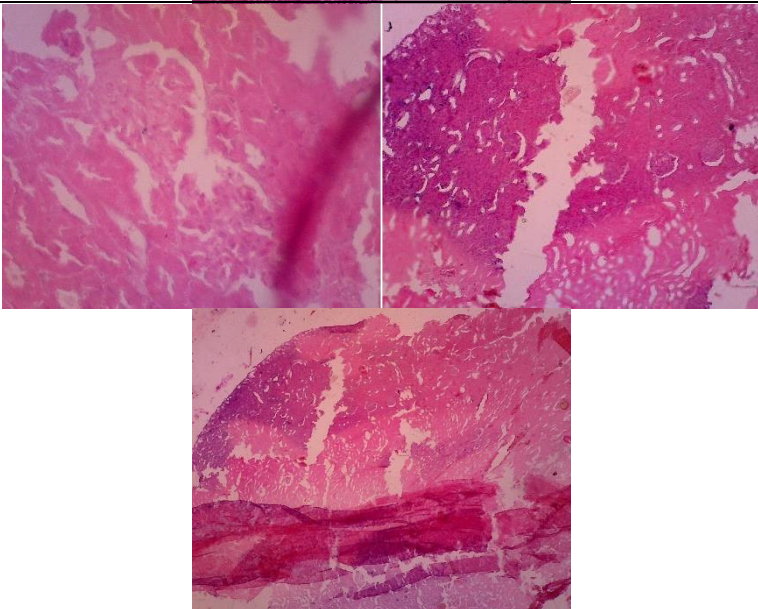


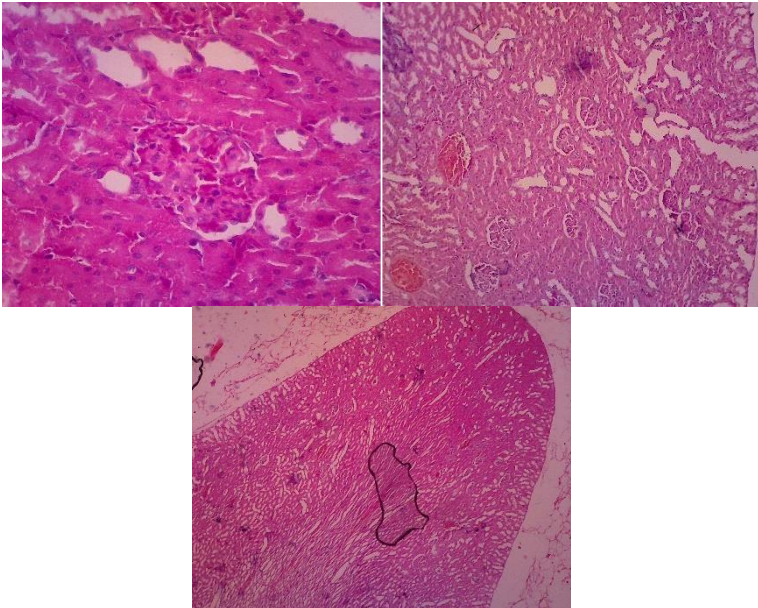
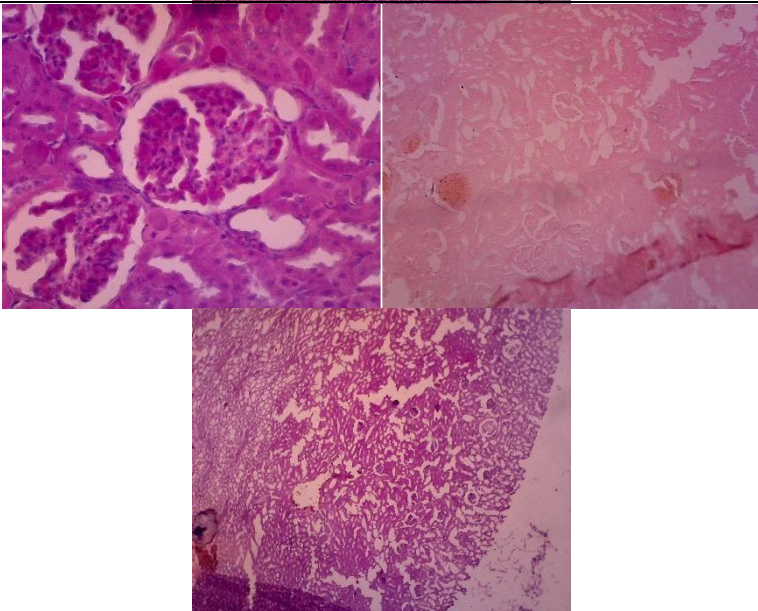
P02+.2		0,85	-
P02+.3		0,68	+

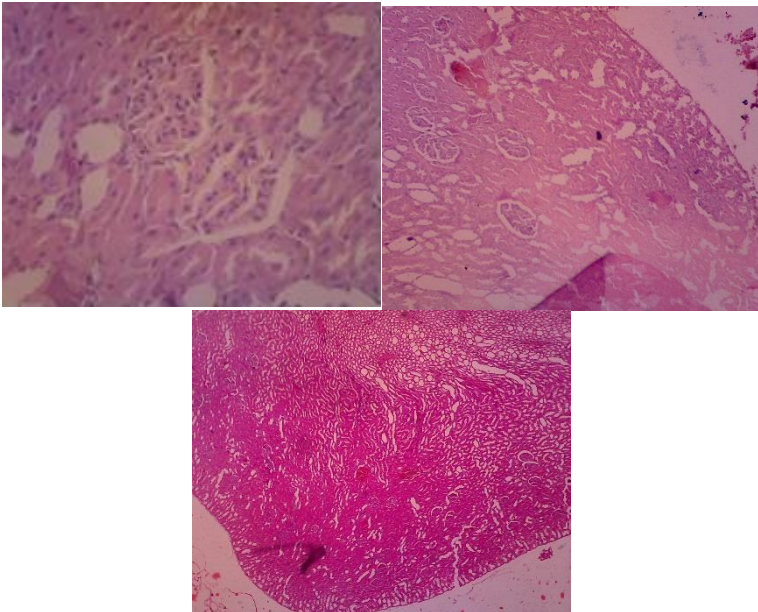
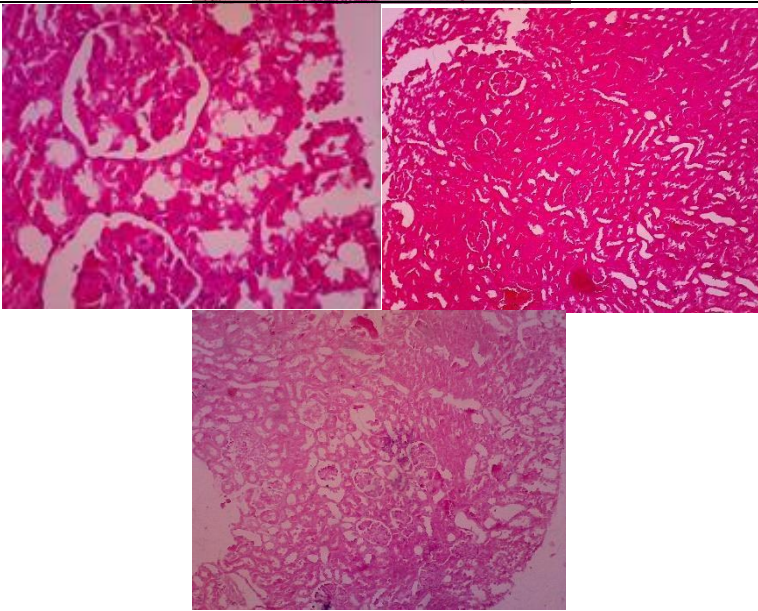
P02+.4		0,78	+
P02+.5		0,85	-

P02+.6		0,69	-
P2.1		0,98	++

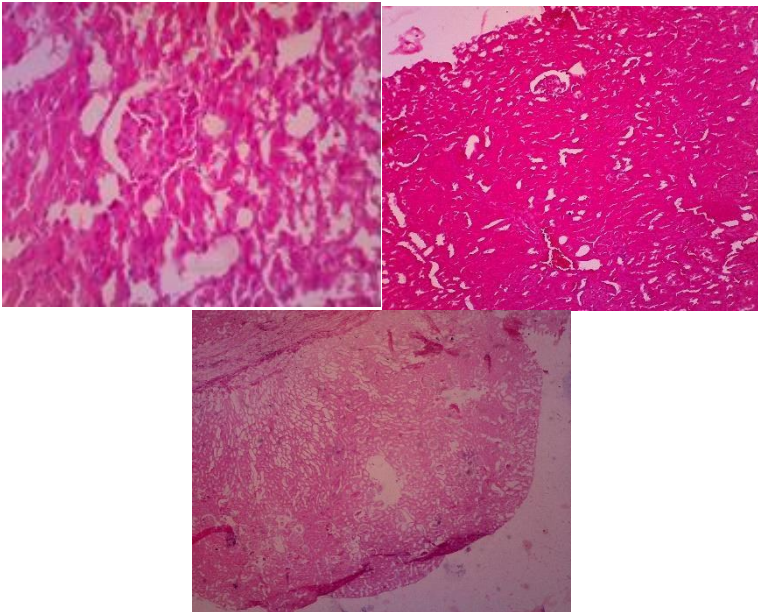
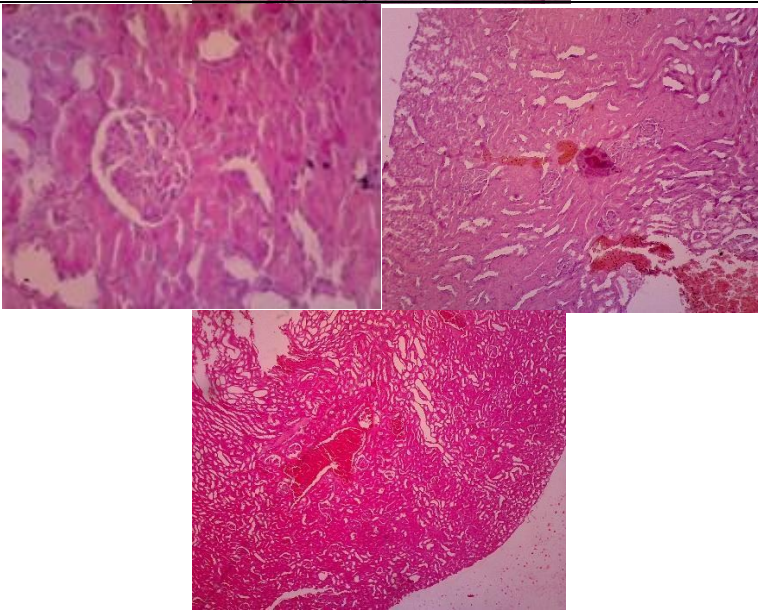


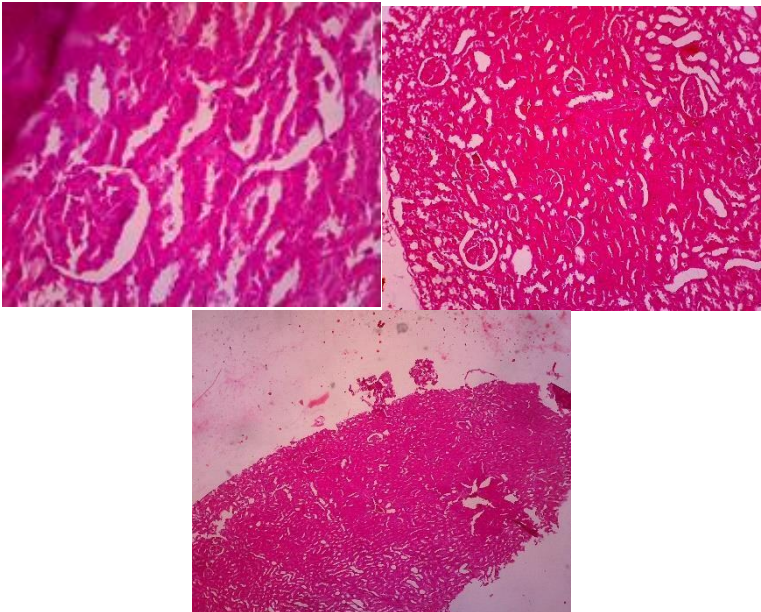
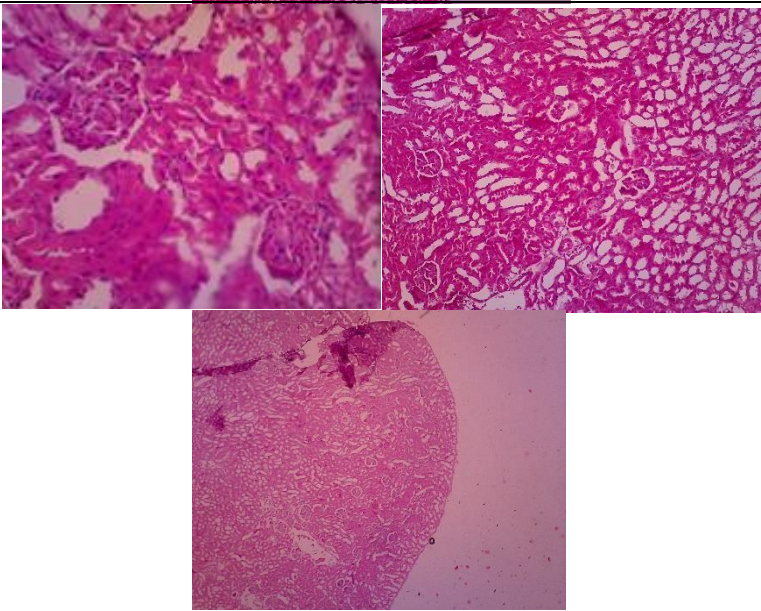
P2.2		0,80	++
P2.3		1,04	++

P2.4		0,97	++
P2.5		0,81	+

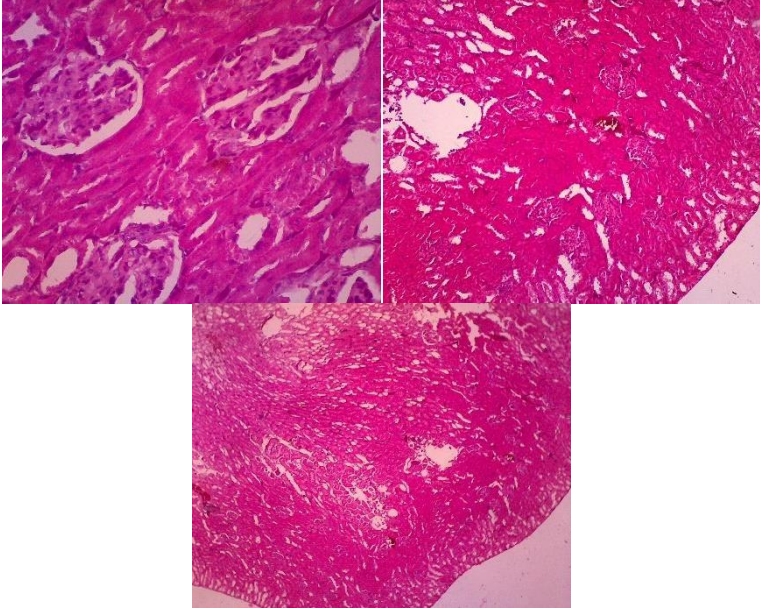
P2.6		1,05	+
P2+.1		0,94	++



P2+.2		0,97	+
P2+.3		1,10	++

P2+.4		0,93	+
P2+.5		0,98	+



P2+.6		1,12	++
-------	--	------	----

Lampiran 3. Daftar Berat Organ Ginjal

3	0.89	0.91	6	3	0.91	0.88	6
2	1.09	1.10	5	2	0.79	0.77	5
1	1.05	1.05	4	1	0.70	0.69	4
	P1				P1+		
3	0.74	0.76	6	3	0.65	0.65	6
2	0.71	0.70	5	2	0.70	0.68	5
1	0.78	0.74	4	1	0.75	0.76	4
	P01				P01+		
3	0.83	0.82	6	3	0.68	0.69	6
2	0.85	0.88	5	2	0.85	0.85	5
1	0.78	0.77	4	1	0.79	0.78	4
	P02				P02+		
3	1.04	1.05	6	3	1.04	1.05	6
2	0.80	0.81	5	2	0.97	0.98	5
1	0.98	0.97	4	1	0.94	0.93	4
	P2				P2+		

Lampiran 4. Daftar Rata-Rata Berat Organ Ginjal

kode	Kanan (gram)	Kiri (gram)	Total (gram)
P01	0,6134	0,7150	0,6642
P1	0,9050	0,9000	0,9025
P02	0,7967	0,7983	0,7975
P2	0,9717	0,9787	0,9742

Lampiran 5. Hasil Penimbangan Berat Badan Tikus

Kelompok perlakuan	Berat Badan Tikus Sebelum Diberi Perlakuan (gram)	Berat Badan Tikus Setelah Diberi Perlakuan
P01	180,83	198,50
P1	181,34	233,83
P02	172,08	189,75
P2	168,42	229,75

Lampiran 6. Hasil Analisa Data Menggunakan SPSS

BETINA

Descriptives

Perlakuan			Statistic	Std. Error
hasil	kontrol	Mean	1.17	.167
		95% Confidence Interval for Lower Bound	.74	
		Mean Upper Bound	1.60	
		5% Trimmed Mean	1.13	
		Median	1.00	
		Variance	.167	
		Std. Deviation	.408	
		Minimum	1	
		Maximum	2	
		Range	1	
		Interquartile Range	0	
		Skewness	2.449	.845
		Kurtosis	6.000	1.741
	perlakuan	Mean	2.60	.245
		95% Confidence Interval for Lower Bound	1.92	
		Mean Upper Bound	3.28	
		5% Trimmed Mean	2.61	
		Median	3.00	
		Variance	.300	
		Std. Deviation	.548	
		Minimum	2	
		Maximum	3	
		Range	1	
		Interquartile Range	1	
		Skewness	-.609	.913
		Kurtosis	-3.333	2.000



**Tests of Normality**

perlakuan	Kolmogorov-Smirnov <sup>a</sup>			Shapiro-Wilk		
	Statistic	Df	Sig.	Statistic	df	Sig.
hasil kontrol	.492	6	.000	.496	6	.000
perlakuan	.367	5	.026	.684	5	.006

a. Lilliefors Significance Correction

**Ranks**

perlakuan	N	Mean Ran
hasil kontrol	6	3
perlakuan	6	9
Total	12	

**Test Statistics<sup>b</sup>**

	hasil
Mann-Whitney U	1.000
Wilcoxon W	22.000
Z	-2.900
Asymp. Sig. (2-tailed)	.004
Exact Sig. [2*(1-tailed Sig.)]	.004 <sup>a</sup>

a. Not corrected for ties.

b. Grouping Variable: perlakuan

# JANTAN

## Descriptives

perlakuan			Statistic	Std. Error
hasil	kontrol	Mean	1.33	.211
		95% Confidence Interval for Mean		
		Lower Bound	.79	
		Upper Bound	1.88	
		5% Trimmed Mean	1.31	
		Median	1.00	
		Variance	.267	
		Std. Deviation	.516	
		Minimum	1	
		Maximum	2	
		Range	1	
		Interquartile Range	1	
		Skewness	.968	.845
		Kurtosis	-1.875	1.741
	perlakuan	Mean	2.67	.211
		95% Confidence Interval for Mean		
		Lower Bound	2.12	
		Upper Bound	3.21	
		5% Trimmed Mean	2.69	
		Median	3.00	
		Variance	.267	
		Std. Deviation	.516	
		Minimum	2	
		Maximum	3	
		Range	1	
		Interquartile Range	1	
		Skewness	-.968	.845
		Kurtosis	-1.875	1.741

**Tests of Normality**

		Kolmogorov-Smirnov <sup>a</sup>			Shapiro-Wilk		
		Statistic	df	Sig.	Statistic	df	Sig.
hasil	kontrol	.407	6	.002	.640	6	.001
	perlakuan	.407	6	.002	.640	6	.001

a. Lilliefors Significance Correction

**Ranks**

perlakuan		N	Mean Rank
hasil	kontrol	6	3
	perlakuan	6	9
Total		12	

**Test Statistics<sup>b</sup>**

	hasil
Mann-Whitney U	2.000
Wilcoxon W	23.000
Z	-2.708
Asymp. Sig. (2-tailed)	.007
Exact Sig. [2*(1-tailed Sig.)]	.009

a. Not corrected for ties.

b. Grouping Variable: perlakuan



Lampiran 7. Kode Etik Penelitian



KEMENTERIAN PENDIDIKAN DAN KEBUDAYAAN  
 UNIVERSITAS HASANUDDIN FAKULTAS KEDOKTERAN  
 KOMITE ETIK PENELITIAN KESEHATAN  
 RSPTN UNIVERSITAS HASANUDDIN  
 RSUP Dr. WAHIDIN SUDIROHUSODO MAKASSAR  
 Sekretariat : Lantai 2 Gedung Laboratorium Terpadu  
 JL.PERINTIS KEMERDEKAAN KAMPUS TAMALANREA KM.10 MAKASSAR 90245.  
 Contact Person: dr. Agussalim Bukhari,,MMed,PhD, SpGK. Telp. 081241850858, 0411 5780103. Fax : 0411-581431



**REKOMENDASI PERSETUJUAN ETIK**  
 Nomor : 80/UN4.6.4.5.31/ PP36/ 2021

Tanggal: 11 Februari 2021

Dengan ini Menyatakan bahwa Protokol dan Dokumen yang Berhubungan Dengan Protokol berikut ini telah mendapatkan Persetujuan Etik :

No Protokol	UH21010055	No Sponsor	
Peneliti Utama	<b>drh. Dian Fatmawati</b>	Sponsor	
Judul Peneliti	Pengaruh tindakan sterilisasi terhadap remodelling tulang dan kadar calcium darah		
No Versi Protokol	1	Tanggal Versi	28 Januari 2021
No Versi PSP		Tanggal Versi	
Tempat Penelitian	<b>Klinik Hewan Pendidikan Universitas Hasanuddin Makassar</b>		
Jenis Review	<input checked="" type="checkbox"/> Exempted <input type="checkbox"/> Expedited <input type="checkbox"/> Fullboard Tanggal	Masa Berlaku <b>11 Februari 2021</b> sampai <b>11 Februari 2022</b>	Frekuensi review lanjutan
Ketua Komisi Etik Penelitian Kesehatan FKUH	Nama <b>Prof.Dr.dr. Suryani As'ad, M.Sc.,Sp.GK (K)</b>	Tanda tangan	
Sekretaris Komisi Etik Penelitian Kesehatan FKUH	Nama <b>dr. Agussalim Bukhari, M.Med.,Ph.D.,Sp.GK (K)</b>	Tanda tangan	

**Kewajiban Peneliti Utama:**

- Menyerahkan Amandemen Protokol untuk persetujuan sebelum di implementasikan
- Menyerahkan Laporan SAE ke Komisi Etik dalam 24 Jam dan dilengkapi dalam 7 hari dan Lapor SUSAR dalam 72 Jam setelah Peneliti Utama menerima laporan
- Menyerahkan Laporan Kemajuan (progress report) setiap 6 bulan untuk penelitian resiko tinggi dan setiap setahun untuk penelitian resiko rendah
- Menyerahkan laporan akhir setelah Penelitian berakhir
- Melaporkan penyimpangan dari prokol yang disetujui (protocol deviation / violation)
- Mematuhi semua peraturan yang ditentukan

## RIWAYAT HIDUP



Penulis dengan nama lengkap Azizah Khaerunnisa lahir di Makassar pada tanggal 5 Januari 2000 dari ayahanda Ruhul Arqam Z. dan Ibunda Eva Arifah Aliyah. Penulis merupakan anak kedua dari keempat bersaudara dengan kakak Afifah Nurul Azizah dan Adik Muh. Ikhsanul Karim serta Muh. Wildan Argantana. Penulis menyelesaikan sekolah dasar di SDIT Al-Biruni Makassar dan lulus pada tahun 2011 dengan program akselerasi kemudian melanjutkan studinya di SMPN 6 Makassar dan lulus pada tahun 2014, kemudian melanjutkan studinya di SMA Internasional Budi Mulia Dua Yogyakarta dan lulus pada tahun 2017. Penulis diterima di Program Studi Kedokteran Hewan Fakultas Kedokteran Universitas Hasanuddin pada tahun 2017 melalui jalur mandiri. Selama perkuliahan penulis aktif di organisasi internal kampus yaitu Himpunan Mahasiswa Kedokteran Hewan (HIMAKAHA) FK-U UNHAS dan menjabat sebagai Dewan Perwakilan (DP) HIMAKAHA FK-UNHAS periode 2019-2020 dan 2020-2021. Penulis juga aktif dalam kegiatan akademik dan pernah menjabat sebagai Asisten Laboratorium Bedah Veteriner pada tahun 2020-2021. Penulis menyusun skripsi dengan judul penelitian **“Gambaran Histoatologi Ginjal pada Tikus Putih (*Rattus norvegicus*) Jantan Orchiectomy dan Betina Ovariohysterectomy”**.