

## DAFTAR PUSTAKA

1. Adam Graeber; Nathan D. Cecava, **Vertebral Osteomyelitis**, Brooke Army Medical Center San Antonio and Uniformed Services Health Care System, Florida - USA, 2022. StatPearls Publishing.
2. Akiyama T, Chikuda H, Yasunaga H, et al. **Incidence and risk factors for mortality of vertebral osteomyelitis: a retrospective analysis using the Japanese diagnosis procedure combination database**. *BMJ Open* 2013;3:e002412. doi:10.1136/bmjopen-2012-002412
3. Bernhard J. Tins<sup>1</sup>, Victor N. Cassar-Pullicino<sup>1</sup>, **MR Imaging of Spinal Infection**, <sup>1</sup>Department of Radiology, The Robert Jones & Agnes Hunt Orthopaedic Hospital, Oswestry, Shropshire, United Kingdom, 2004
4. Boll DT, Bulow H, Blackham KA, Aschoff AJ, Schmitz BL. **MDCT angiography of the spinal vasculature and the artery of Adamkiewicz**. *AJR Am J Roentgenol*. 2006 Oct;187(4):1054-60.
5. Burns, J. E., Yao, J., & Summers, R. M. (2017). **Vertebral Body Compression Fractures and Bone Density: Automated Detection and Classification on CT Images**. *Radiology*, 284(3), 788–797. doi:10.1148/radiol.2017162100
6. Chankue Parka, Joon Woo Leeb, Yongju Kimb, Soyeon Ahnc, Eugene Leeb, Yusuhn Kangb, Heung Sik Kang, **Diagnosis of spinal metastasis: are MR images without contrast medium application sufficient?**, Department of Radiology, Pusan National University Yangsan Hospital, Department of Radiology, Seoul National University Bundang Hospital, Republic of Korea. <https://doi.org/10.1016/j.clinimag.2019.03.003>. 2019
7. Chansik An, Young Han Lee, Sungjun Kim, Hee Woo Cho, Jin-Suck Suh, Ho-Taek Song, **Characteristic MRI Findings of Spinal Metastases from Various Primary Cancers: Retrospective Study of Pathologically-Confirmed Cases**, Department of Radiology and Research Institute of Radiological Science, Yonsei University College of Medicine, Seoul, Korea. 2013.
8. Choi D, Crockard A, Bungler C, et al. **Review of metastatic spine tumour classification and indications for surgery: the consensus statement of the Global Spine Tumour Study Group**. *Eur Spine J* 2010;19:215-222.
9. Das, C., Baruah, U., & Panda, A. (2014). **Imaging of vertebral fractures**.

- Indian Journal of Endocrinology and Metabolism, 18(3), 295.  
doi:10.4103/2230-8210.131140
10. Derek W. Moore MD, **Adult Pyogenic Vertebral Osteomyelitis**, Cited Online on : <https://www.orthobullets.com/spine/2025/adult-pyogenic-vertebral-osteomyelitis>. Ortho Bullets, Orthopaedic Journals. 2021
  11. Dong Hoon Lee , Jong Kil Nam, Hee Suk Jung, Seong Jang Kim, Moon Kee Chung , Sung-Woo Park, **Does T1- and diffusion-weighted magnetic resonance imaging give value-added than bone scintigraphy in the follow-up of vertebral metastasis of prostate cancer?**, Departments of Urology, Radiology, Nuclear Medicine, and Research Institute for Convergence of Biomedical Science and Technology, Pusan National University Yangsan Hospital, Yangsan, Korea, Investigate and clinical urology. [www.icurology.org](http://www.icurology.org). <https://doi.org/10.4111/icu.2017.58.5.324>, 2017
  12. Drake RL, Vogl AW, Mitchell AWM. Back. In: **Gray's Anatomy for Students**, Fourth Edition. Elsevier. 2020: p.51-83.
  13. E. Mylona, MD, M. Samarkos, E. Kakalou, P. Fanourgiakis, and A. Skoutelis, **Pyogenic Vertebral Osteomyelitis: A Systematic Review of Clinical Characteristics**, doi:10.1016/j.semarthrit.2008.03.002. 2008 Elsevier Inc. All rights reserved.
  14. Ekramul M. Gofur, Paramvir Singh. **Anatomy, Back, Vertebral Canal Blood Supply**, NCBI Bookshelf. A service of the National Library of Medicine, National Institutes of Health. Treasure Island (FL): 2022. StatPearls Publishing;
  15. G. Guglielmi D. Diacinti C. van Kuijk F. Aparisi C. Krestan J. E. Adams T. M. Link, **Vertebral morphometry: current methods and recent advances**, G. Guglielmi Department of Radiology, Scientific Institute Hospital, San Giovanni Rotondo, Italy, European Radiology Journal <https://www.researchgate.net/publication/5501801>. 2008
  16. Giulio Maccauro,<sup>1</sup> Maria Silvia Spinelli,<sup>1</sup> Sigismondo Mauro,<sup>2</sup> Carlo Perisano,<sup>1</sup> Calogero Graci,<sup>1</sup> dan Michele Attilio Rosa<sup>2</sup>, Tinjauan Artikel Fisiopatologi Metastasis Tulang Belakang, <sup>1</sup>Departemen Ortopedi dan Traumatologi, Rumah Sakit Agostino Gemelli, Universitas Katolik, L.go F Vito, 1-00168 Roma, Italia <sup>2</sup>Departemen Ortopedi, Universitas Messina, Via Consolare Valeria, 1-98122 Messina, Italia – 2011

17. Gregory D. Cramer & Susan A. Darby, **2. General Characteristics of the Spine “Clinical Anatomy of the Spine, Spinal Cord, and ANS”, 3rd Edition**, Department of Anatomy, National University of Health Science, Lombard, IL, USA. 2014
18. Howard S. An, MD; and J. Alex Seldomridge, MD, MBA, **Spinal Infections Diagnostic Tests and Imaging Studies**, CLINICAL ORTHOPAEDICS AND RELATED RESEARCH Number 444, pp. 27–33, 2006 Lippincott Williams & Wilkins
19. J. F. Ratcliffe, **Anatomic Basis For The Pathogenesis And Radiologic Features Of Vertebral Osteomyelitis And Its Differentiation From Childhood Discitis**, The Department Of Radiodiagnosis, Booth Hall Children's Hospital, Manchester M9 2aa, England. 1985
20. Janice L. Hinkle, PhD, RN, CNRN, Kerry H. Cheever, **Brunner & Suddarth’s - Textbook of Medical-Surgical Nursing, Twelfth Edition**, The Catholic University of America Washington, DC and Department of Nursing Moravian College Bethlehem, Pennsylvania. 2014
21. John T. Schousboe, **Epidemiology of Vertebral Fractures**, Park Nicollet Osteoporosis Center, Park Nicollet Clinic, HealthPartners, Minneapolis, MN, USA; and 2 Division of Health Policy and Management, School of Public Health, University of Minnesota, Minneapolis, MD, USA, Journal of Clinical Densitometry: Assessment & Management of Musculoskeletal Health, <http://dx.doi.org/10.1016/j.jocd.2015.08.004>. 2015
22. Jorge Juan Fragío, Roxana González Mazaríoa, Miguel Salavert Lleti, José Andrés Román Ivorra, **Vertebral osteomyelitis: Clinical, microbiological and radiological characteristics of 116 patients**, Rheumatology Department and Infectious Diseases Unit, Hospital Universitari i Politècnic La Fe, Valencia, Spain, 2020. Elsevier .All right reserved
23. Julio Arevalo-Perez, MD, Kyung K. Peck, PhD, John K. Lyo, MD, Andrei I. Holodny, MD, Eric Lis, MD, and Sasan Karimi, MD, **Differentiating Benign From Malignant Vertebral Fractures Using T1-Weighted Dynamic Contrast-Enhanced MRI**, Department of Radiology, Memorial Sloan-Kettering Cancer Center, 1275 York Ave., New York, 2015
24. K.A. Tomaszewski, K. Saganiak, T. Gładysz, J.A. Walocha, **The biology behind the human intervertebral disc and its endplates**, Dept. of

- Anatomy and Dept. of Oral Surgery, Jagiellonian University Medical College, Krakow, Poland. 2015
25. Kyung Ryeol Lee, M.D. **Interpretation of MR Imaging of Spinal Metastasis: Focus on the Understanding of Its Pathophysiology and the Next Step toward a Further Clinical Approach Using MRI Findings**, Department of Radiology, Jeju National University Hospital, Aran 13 gil 15 (Ara-1-dong), Jeju-si, Jeju Special Self Governing Province 63241, <http://dx.doi.org/10.13104/imri.2016.20.1.1>. Korea. 2016
  26. Li, Z, Guan, M., Sun, D. *et al.* **A novel MRI- and CT-based scoring system to differentiate malignant from osteoporotic vertebral fractures in Chinese patients.** *BMC Musculoskelet Disord* **19**, 406 (2018). <https://doi.org/10.1186/s12891-018-2331-0>
  27. Lubdha M. Shah and Karen L. Salzman, Review Article Imaging of Spinal Metastatic Disease, Neuroradiology Division, Department of Radiology, School of Medicine, The University of Utah, 1A71 SOM, 50 N. Medical Drive, Salt Lake City, UT 84132, USA, 2011
  28. Mahesh V. Jayaraman, **Preoperative and Therapeutic Endovascular Approaches for Spinal Tumors**, Department of Diagnostic Imaging, Neurology and Neurosurgery. Rhode Island Hospital, Neupsy-Key Nuerosurgery Journals, 2016
  29. Maus, T. P. **Imaging of the spine and nerve roots.** *Physical Medicine and Rehabilitation Clinics of North America*, WBS Journals 13(3), 487–544. doi:10.1016/s1047-9651(02)00009-8. 2002
  30. Max Aebi, **Spinal metastasis in the elderly**, *Europe Spine Journal* Vol. 12 (Suppl. 2) : S202–S213 DOI 10.1007/s00586-003-0609-9. 2003. Springer-Verlag publishing.
  31. ME Abdel-Wanis, Mohamed Tharwat Mahmoud Solyman, Nahla Mohamed Ali Hasan2, **Sensitivity, specificity and accuracy of magnetic resonance imaging for differentiating vertebral compression fractures caused by malignancy, osteoporosis, and infections**, Department of Orthopaedic Surgery, Sohag Faculty of Medicine, Sohag University, Sohag, Egypt Department of Diagnostic Radiology, Sohag Faculty of Medicine, Sohag University, Sohag, Egypt. *Journal of Orthopaedic Surgery*. 2011

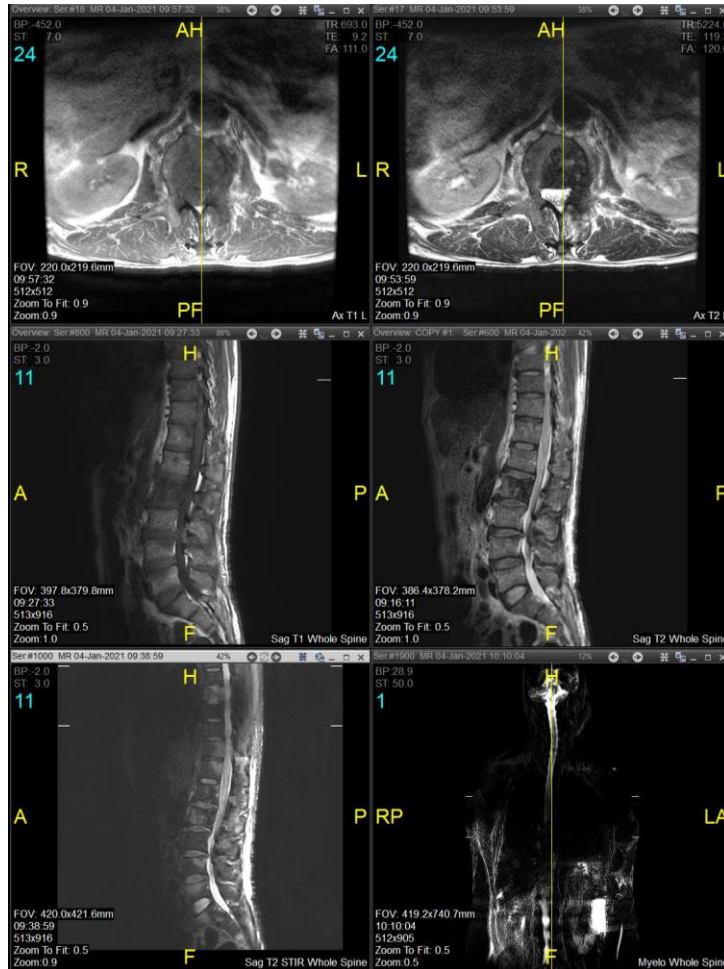
32. Netter, Frank H., John T. Hansen, and David R. Lambert. 2012. **Netter's clinical anatomy. 7<sup>th</sup> Edition**. Carlstadt, N.J.: Icon Learning Systems.
33. Nikolai Bogduk, **Functional anatomy of the spine, Newcastle Bone and Joint Institute**, University of Newcastle, Newcastle, Australia, Handbook of Clinical Neurology, Vol. 136 (3rd series) Neuroimaging, Part II. 2016. Elsevier B.V
34. R. Guillemina,b,\* , j.-n. Valleec , f. Lafittea , c. Menuela , n.-m. Duverneuila , j. Chirasa, **Spine Metastasis Imaging: Review Of The Literature Imagerie Des Métastases Vertébrales : Revue De La Littérature**, service de neuroradiologie professeur-j.-chiras, groupe hospitalier de la pitié-salpêtrière, 47–83, boulevard de l'hôpital, 75651 paris cedex 13, france b laboratoire d'imagerie fonctionnelle, inserm u678, université pierre-et-marie-curie, paris, france c département de neuroradiologie, chu d'amiens, france, 2007
35. Ravindra Kumar Garg, Dilip Singh Somvanshi , **Review Spinal tuberculosis: A review** Chhatrapati Shahuji Maharaj Medical University, Lucknow, Uttar Pradesh, India, 2011)
36. Robert E. Coleman, Peter I. Croucher, Anwar R. Padhani, Philippe Clézardin, Edward Chow, Marie Fallon, Theresa Guise, Simone Colangeli, Rodolfo Capanna and Luis Costa, **Bone metastases**, NATURE REVIEWS | DISEASE PRIMERS, <https://doi.org/10.1038/s41572-020-00216-3>, 2020.
37. S. Ohlmann-Knafo, A. D. Tarnoki, D. L. Tarnoki, D. Pickuth, **MR Diagnosis of Bone Metastases at 1.5 T and 3 T: Can STIR Imaging Be Omitted?**, Department of Diagnostic and Interventional Radiology, Caritasklinikum Saarbrücken St. Theresia, Saarbrücken, Germany, <http://dx.doi.org/10.1055/s-0035-1553207>. 2015
38. Shawn M. Vuong, MD, William J. Jeong, MD, Humberto Morales, MD, and Todd A. Abruzzo, MD, **Vascular Diseases of the Spinal Cord: Infarction, Hemorrhage, and Venous Congestive Myelopathy**, University of Cincinnati College of Medicine, Cincinnati, OH. <http://dx.doi.org/10.1053/j.sult.2016.05.008>. 2016
39. Shrey K. Thawait , MD, Matthew A. Marcus , MD, William B. Morrison, MD, Roman A. Klufas, MD , John Eng , MD , and John A. Carrino , MD, MPH, **Research Synthesis: What Is the Diagnostic Performance of Magnetic**

**Resonance Imaging to Discriminate Benign From Malignant Vertebral Compression Fractures?**, Yale University, Bridgeport hospital, Bridgeport, CT; Pitts Radiology, Columbia, SC; Thomas Jefferson University Hospital, Philadelphia, PA; Brigham and Women's Hospital, Boston, MA; Johns Hopkins School of Medicine, Baltimore, MD; and ¶Johns Hopkins Hospital, Baltimore, MD. *SPINE* Volume 37, Number 12, pp E736–E744, 2012, Lippincott Williams & Wilkins

40. Sung Hwan Hong, MD • Ja-Young Choi, MD • Joon Woo Lee, MD • Na Ra Kim, MD • Jung-Ah Choi, MD • Heung Sik Kang, MD, R **Imaging Assessment of the Spine: Infection or an Imitation?**<sup>1</sup>, From the Department of Radiology and Institute of Radiation Medicine, Seoul National University College of Medicine, 28 Yongon-dong, Chongno-gu, Seoul 110-744, South Korea. Presented as an education exhibit at the 2007
41. William T.C, Jerome P. Quets, Han J lee, Tereasa M. Simonson, Linda S. Michlason, Phan T, Nguyen, Yutaka sato, Nina a.Mays, and kevin S, Berbaum, **Anatomic Distribution of Metastases in the Vertebral body and Modes of Hematogenous spread**, *SPINE Journals* Volume 21, November 19, pp 2243-2250, Lippincott-Raven Publisher. 1996
42. Y. Fujii. Y. Higashi, F. Owada, T. Okuno, Hitomi mizuno and Hideaki Mizuno, **Magnetic Resonance Imaging For The Diagnosis Of Prostate Cancer Metastatic To Bone**, Department of Urology and Radiology, Omiya Red Cross Hospital, Saitama, Japan. 1995
43. Yasuaki Tokuhashi, Hiroshi Uei, Masashi Oshima, Yasumitsu Ajiro, **Classification and scoring systems for metastatic spine tumors: a literature review**, Department of Orthopedic Surgery, Nihon University School of Medicine, Japan. *Spine Surg Relat Res* 2017; 1(2): 44-55 [dx.doi.org/10.22603/ssrr.1.2016-0021](https://doi.org/10.22603/ssrr.1.2016-0021)
44. Yusuke Yamamoto A, Eiichiro Iwata B, Hideki Shigematsu A, Toshiya Morita C, Masato Tanaka A, Akinori Okuda A, Keisuke Masuda A, Masaki Ikejiri D, Hiroshi Nakajima D, Munehisa Koizumi e, Yasuhito Tanaka, **Differential diagnosis between metastatic and osteoporotic vertebral fractures using sagittal T1-weighted magnetic resonance imaging**, Nara Prefecture General Medical Center, Japan, *Journal of Orthopaedic Science*. 2019. Elsevier Publishing

## LAMPIRAN - LAMPIRAN

### Lampiran 1 : Hasil Pemeriksaan MRI Vertebra Pasien dengan Fraktur Vertebra Metastasis



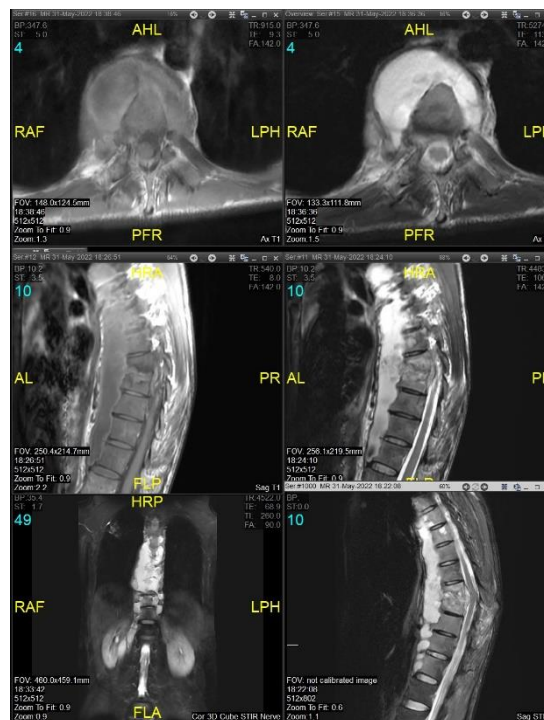Gambar 1. MRI Vertebra Thoracolumbal tanpa Kontras T1WI, T2WI, STIR dan Myelografi dari Pasien Laki-Laki 926690, menunjukkan Moderate Compression Fracture (Klas. Genant) pada CV L2 dengan lesi litik, intensitas bone marrow yang hipointens di T1WI, heterogen di T2WI dan STIR. Tampak pula multiple penurunan intensitas bone marrow yang diffus pada CV regio horacolumbal di sequens T1WI. Tampak discus intervertebralis dalam batas normal. Pada potongan axial tampak lesi osteoblastik pada regio posterior corpus vertebra. Tampak pula penebalan irreguler pada soft tissue paravertebral, semua khas untuk temuan metastasis tumor ke collumna vertebralis.

## Lampiran 2 : Hasil Pemeriksaan Patologi Anatomi

Bahan / Lokalisasi	: Vertebra
Keterangan Klinik	: Pasien tidak dapat menggerakkan kedua kaki dialami sejak 17 Desember 2020 yang dirasakan secara tiba-tiba. Awalnya pasien mengeluh nyeri pada punggung bawah dialami sejak November 2020. Pasien riwayat mengangkat barang berat. Tidak ada trauma. Riwayat operasi prostat tahun 2018. Pasien juga mengeluh tidak dapat merasakan buang air kecil dan buang air besar.
Diagnosis Klinik	: Paraplegia due to Destruction vertebra Thoracal VIII and Lumbal
Pemeriksaan PA	: Blok Parafin
Makroskopik	: Diterima 2 wadah jaringan. Wadah I: Jaringan tidak beraturan sebanyak 3cc. Ada bagian yang keras (tulang). Dibuat 2 kaset. Semua cetak. Wadah II: Jaringan tidak beraturan sebanyak 1cc, ada bagian keras, warna kecoklatan, konsistensi padat. Dibuat 1 kaset, semua cetak.
Mikroskopik	: IA, IB. Sediaan jaringan asal lamina terdiri dari jaringan tulang, jaringan lemak, diantaranya terdapat beberapa struktur menyerupai kelenjar dengan inti hiperkromatik, pleomorfik, dengan beberapa nukleoli tampak prominen. II. Sediaan jaringan asal canalis spinalis terdiri dari jaringan tulang, jaringan tulang nekrotik dengan sebaran sel-sel radang netrofil padat, jaringan ikat dan sebaran sel yang tersusun solid dengan inti cukup besar, atipik, pleomorfik dan nukleoli prominen.
Kesimpulan	: METASTASIS BONE DISEASE KESAN SUATU ADENOCARCINOMA (TERUTAMA PADA SLIDE IB) ICD O: C41.2 - 8140/6

Lampiran 2. Laporan Patologi Anatomi Pasien pada gambar 1. Sampel diambil saat operasi pemasangan stabilisator posterior pada pasien.

## Lampiran 3 : Hasil Pemeriksaan MRI Vertebra Pasien dengan Fraktur Vertebra Infeksi



Gambar 2. MRI Vertebra Thoracalis tanpa kontras pada pasien 980034. Tampak destruksi pada multiple CV regio thoracalis terutama pada endplate tanpa lesi litik, destruksi endplate terjadi pada dua CV yang berdekatan dengan intensitas bone marrow yang isointens di T1WI dan hiperintens di T2WI dan STIR, tampak keterlibatan discus intervertebralis dan pembentukan soft tissue abscess paravetebra

## Lampiran 4 : Hasil Pemeriksaan Laboratorium Pasien dengan Fraktur



## Vertebra Infeksi

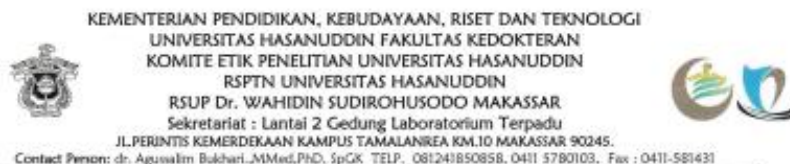Nomor RM	: 980034	No. Registrasi	: 20220705951001105616343
Nama Pasien	:	Tgl. Registrasi	: 05-07-2022 10:09:10
Jns Kelamin/Tgl.Lahir	: Laki-Laki 10-12-1985	Tgl. Hasil	: 06-07-2022 09:15:08
Nomor Lab	: RJ0171	Unit Pengantar	: null
Diagnosa	:	Dokter Perujuk	: Dr. dr. Asvin Nurulita, M.Kes, Sp.PK (K)

PEMERIKSAAN	HASIL	NILAI RUJUKAN	SATUAN
RUJUKAN LUAR			
Molekuler			
Spesimen	Dahak	-	
Deteksi Mycobacterium Tuberculosis	Terdeteksi	Tidak Terdeteksi	
Tes Rifampicin	Sensitif	Sensitif	

Halaman 1 / 1

Lampiran 4 . hasil Pemeriksaan Sputum BTA pasien pada gambar 3 (Lampiran 3) menunjukkan terdeteksi Mycobacterium TB.

**Lampiran 5 : Izin dari Komisi Etik Penelitian Universitas Hasanuddin – RSPN UNHAS – RSUP Dr.Wahidin Sudirohusodo**



**REKOMENDASI PERSETUJUAN ETIK**

Nomor : 549/UN4.6.4.5.31/ PP36/ 2022

Tanggal: 29 September 2022

Dengan ini Menyatakan bahwa Protokol dan Dokumen yang Berhubungan Dengan Protokol berikut ini telah mendapatkan Persetujuan Etik :

No Protokol	UH22080453		No Sponsor	
Peneliti Utama	<b>dr. Dwi Maheza Malik</b>		Sponsor	
Judul Peneliti	PERBANDINGAN GAMBARAN MRI DARI PERUBAHAN PATOLOGIS ELEMEN COLUMNNA VERTEBRALIS PADA FRAKTUR VERTEBRA METASTASIS DAN FRAKTUR VERTEBRA INFEKSI			
No Versi Protokol	<b>1</b>	Tanggal Versi	<b>18 Agustus 2022</b>	
No Versi PSP		Tanggal Versi		
Tempat Penelitian	RSUP Dr. Wahidin Sudirohusodo Makassar			
Jenis Review	<input type="checkbox"/> Exempted <input checked="" type="checkbox"/> Expedited <input type="checkbox"/> Fullboard Tanggal	Masa Berlaku	Frekuensi review lanjutan	
		29 September 2022 sampai 29 September 2023		
Ketua KEP Universitas Hasanuddin	Nama <b>Prof.Dr.dr. Suryani As'ad, M.Sc.,Sp.GK (K)</b>	Tanda tangan		
Sekretaris KEP Universitas Hasanuddin	Nama <b>dr. Agussalim Bukhari, M.Med.,Ph.D.,Sp.GK (K)</b>	Tanda tangan		

Kewajiban Peneliti Utama:

- Menyerahkan Amandemen Protokol untuk persetujuan sebelum di implementasikan
- Menyerahkan Laporan SAE ke Komisi Etik dalam 24 jam dan dilengkapi dalam 7 hari dan Laporan SUSAR dalam 72 Jam setelah Peneliti Utama menerima laporan
- Menyerahkan Laporan Kemajuan (progress report) setiap 6 bulan untuk penelitian resiko tinggi dan setiap setahun untuk penelitian resiko rendah
- Menyerahkan laporan akhir setelah Penelitian berakhir
- Melaporkan penyimpangan dari protokol yang disetujui (protocol deviation / violation)
- Mematuhi semua peraturan yang ditentukan

## Lampiran 6 : Form Data Sampel

DATA SAMPEL PENELITIAN MRI VERTEBRA METASTASIS

NO	REKAM MEDIK	INISIAL PASIEN	TGL PEMERIKSAAN MRI	DIAGNOSA RADIOLOGI	HASIL MRI	DIAGNOSA KLINIS	JK	UMUR (THN)	REGIO MRI VT	GRADE FR. (GENANT)	JUMLAH CORPUS TERLIBAT	P1	P2-1	P2-2	P3-1	P3-2	P4	P5	PA / RIW OPERASI	PRIMER TUMOR
												TYP E LESI	BONE MARROW	DISCUS INT	SO FT TISSUE	EP	+/-			
1.	979463	TC	25-05-2022	CA. MAMMAE DEXTRA	MBD	CA. MAMMAE DEX	P	58	TH-LS	MILD	>1	-1A	-2A1	-2C2	0	0	-4A1	-5A	+ PA	CA. MAMMAE
2.	968182	AJ	01-03-2022	PARAPARESE UMN	MBD	CA. MAMMAE DEX	L	58	TH-LS	MILD	>1	-1A	-2A1	-2C2	0	0	-4A1	-5B	+ PA	CA. MAMMAE
3.	965668	SM	08-02-2022	PARAPARESE UMN	MBD	TUMOR RETROPERITONEAL	P	36	WS	MILD	>1	-1A	-2A1	-2C2	0	0	0	-5B	+ PA	CA. RECTI
4.	882993	TS	11-02-2022	SUSP. METAS VERTEBRA	MBD	HIPERTROFI PROSTAT SUSP. MALIGNANCY	P	74	TH	MILD	>1	-1A	-2A1	-2C2	0	0	0	-5A	+ PA	CA. PROSTAT
5.	960360	AK	06-06-2022	PARAPLEGIA FLACCID	MBD	CA. PROSTAT	L	68	TH-LS	MILD	>1	-1A	-2A1	-2B2	0	0	-4A1	-5A	+ PA	CA. PROSTAT
6.	959805	MK	14-01-2022	PARAPARESE UMN	MBD	TU. PARU KIRI	L	55	TH	MILD	>1	-1A	-2A1	-2B2	0	0	0	-5A	+ PA	CA. PARU
7.	926690	EF	04-01-2021	SUSP. MBD	MBD	CA. PROSTAT	L		TH-LS	MILD	>1	-1A	-2C1	-2B2	0	0	-4A1	-5A	+ PA	CA. PROSTAT
8.	74682	MT	30-03-2021	LBP	MBD	TUMOR PARU	L	61	LS	MILD	1	-1B	-2A1	-2C2	0	0	-4B1	-5C	+ PA	CA. PARU
9.	965480	AF	04-02-2022	PARAPARESE	MBD	CA. THYROID BILATERAL	L	62	LS	MILD	>1	-1A	-2A1	-2C2	0	0	-4B1	-5A	+ PA	CA. THYROID

Form 1. Data sampel pasien dengan Fraktur Vertebra Metastasis

DATA SAMPEL PENELITIAN MRI VERTEBRA INFEKSI

NO	VP	INISIAL PASIEN	TGL. PX MRI	D' RADIOLOGI	HASIL MRI	D' KLINIS	JK	UMUR	MRI VT	PV (GENANT)	JUMLAH CORPUS TERLIBAT	P1	P2-1	P2-2	P3-1	P3-2	P4	P5	LAB / PA
												CV	BM	DI	ST	EP	+/-		
1.	985636	MD	04-07-2022	CERVICAL PAIN EC HNP CERVICAL	SPONDYLODISCHITIS	LEUKOSITOSIS	L	37	CV	MILD	>1	+1A	+2A1	+2B2	+3A1	+3B2	+4C2	0	*
2.	986461	SM	12-07-2022	LBP EC SUSPEK HNP	SPONDYLITIS PYOGENIC	LEUKOSITOSIS + ABSSES PARAVERTEBRA	L	47	LS	MILD	>1	+1A	+2A1	+2B2	+3A1	+3B2	+4C2	0	*
3.	982602	IR	30-06-2022	LBP	SPONDYLODISCHITIS	SUSPEK TB	P	35	TH	MILD	>1	+1A	+2A1	+2B2	+3A1	+3B2	+4C2	0	*
4.	970855	AA	16-03-2022	PARAPLEGIA FLACCID	SPONDYLITIS TB	TB LAMA, TB SPINE	L	55	TH	MILD	>1	+1A	+2A1	+2B2	+3A1	+3B2	+4C2	+5A	*
5.	965722	MS	10-02-2022	LBP	SPONDYLITIS TB	TB LAMA	L	44	LS	MILD	>1	+1A	+2A1	+2B2	+3A1	+3B2	+4C2	+5A	*
6.	903476	MF	03-02-2022	LBP	SPONDYLITIS	TB MILIER	L	35	LS	MILD	>1	+1A	+2A1	+2B2	+3A1	+3B2	+4B2	0	*
7.	934790	EP	24-05-2021	SUSP SPONDYLITIS TB	SPONDYLITIS	TB PARU	P	64	TH	MILD	>1	+1A	+2A1	+2B2	+3A1	+3B2	+4C2	0	*
8.	776137	HS	21-09-2022	Paraparese	spondylitis piogenik	DM	P	59	LS	MILD	>1	+1A	+2A1	+2B2	+3B	+3B2	+4C2	+5A	*
9.	992531	KA	12-09-2022	Paraparese UMN	Spondylodiscitis	DM	P	66	LS	MILD	>1	+1A	+2C1	+2C2	+3A1	+3B2	+4C2	0	*
10.	951776	AM	23-06-2022	PARAPLEGI	SPONDYLITIS	CRD, HT GASTROPATI OBAT	L	52	TH	MODERATE	>1	+1A	+2A1	+2B2	+3A1	+3B2	+4C2	0	*
11.	982304	HB	16-06-2022	PARAPARESE UMN	SPONDYLITIS TB	TB LAMA	P	33	TH	MODERATE	>1	+1A	+2A1	+2B2	+3A	+3B2	+4C2	0	*
12.	988135	AR	29-07-2022	PARAPARESE UMN	SPONDYLITIS TB	TB CAT	L	42	TH	MODERATE	>1	+1A	+2A1	+2B2	+3A1	+3B2	+4C2	+5A	*
13.	986490	SD	12-07-2022	TETRAPARESE	SPONDYLITIS TB	TBC	L	60	CV	MODERATE	>1	+1A	+2C1	+2C2	+3A1	+3B2	+4C2	0	*
14.	985696	MT	20-07-2022	TUMOR INTRADURAL EXTRAMEDULLAR	SPONDYLITIS TB	LEUKOSITOSIS	L	32	TH	MILD	1	0	+2A1	+2B2	0	0	+4A2	0	*

Form 2. Data sampel pasien dengan Fraktur Vertebra Infeksi

**Lampiran 7 :**

**CURRICULUM VITAE**

**A. Data Pribadi**

- Nama : dr. Dwi Maheza Malik
- Tempat/ Tanggal Lahir : Merauke, Papua / 11 September 1987
- Alamat : Jl. Borong Raya VI, Komp. Griya Tiara Indah Blok A2 No.5 Makassar
- Agama : Islam

**B. Riwayat Pendidikan**

- SD : SD Kartika Chandra Kirana VII-1 Makassar, lulus Thn. 1999
- SMP : SMP Negeri 13 Bandung, lulus tahun 2002
- SMA : SMA Negeri 2 Makassar, lulus tahun 2005
- Strata-1 (Pendidikan Dokter) : Fakultas Kedokteran Universitas Hasanuddin, Makassar, Angkatan 2005, lulus tahun 2012
- Program Pendidikan Dokter Spesialis-1: Departemen Radiologi Fakultas Kedokteran Universitas Hasanuddin, Makassar, periode Juli 2018

**C. Riwayat Pekerjaan**

- Dokter Klinik Kesehatan Rindam XIV Hasanuddin (PNS), tahun 2014-2018

**D. Riwayat Keluarga**

- Ayah : Mayjen. Pur. TNI H. Husein Malik
- Ibu : Hj. Kartini Rabbah
- Saudara kandung : Dewi Maharani Malik
- Istri : Hj. Nurul Arany Razak, SKM

**E. Karya Ilmiah/ Artikel yang telah dipublikasikan : -**

**F. Makalah pada Seminar/ Konferensi Ilmiah Nasional dan Internasional : -**