

DAFTAR PUSTAKA

1. Alorjani MS, Matalka II, Alfaqih MA, Jahmani RA, Alsinglawi BS, Nimri FM, Matalka MI, Amr SS. Soft Tissue Sarcomas: A 16-Year Experience of a Tertiary Referral Hospital in North Jordan. *Medicina*. 2022 Jan 27;58(2):198.
2. A. Razek et al. (2012). Assessment of soft tissue tumours of the extremities with diffusion echo-planar MR imaging. *Radiol med* 117:96–101
3. Ashkan A. Malayeri, MD. 2011. Principles and Applications of Diffusion-weighted Imaging in Cancer Detection, Staging, and Treatment Follow-up. [Radiographics.rsna.org](http://radiographics.rsna.org)
4. Aziza G ikhsan et al. 2009. Radiology Appearance of Malignant Peripheral Nerve Sheath Tumor: a Case Report. *Indonesian Journal of Cancer* Vol. III, No. 4
5. Carmelo Messina et al. 2020. Diffusion-Weighted Imaging in Oncology: An Update . *Cancers* 2020, 12, 1493; doi:10.3390/cancers12061493
6. Catherina S.P. van Rijswijk et al, 2002. Diffusion-Weighted MRI in the Characterization of Soft-Tissue Tumors. *Journal of Magnetic Resonance Imaging* 15:302–307. DOI 10.1002/jmri.10061
7. Chloé Bonarelli et al. (2015). Impact of ROI Positioning and Lesion Morphology on Apparent Diffusion Coefficient Analysis for the Differentiation Between Benign and Malignant Nonfatty Soft-Tissue Lesions. *AJR* 2015; 205:W106–W113
8. Dane J. Church et al. (2017). Evaluating Soft-Tissue Lumps and Bumps. *Missouri Medicine* July/August 2017 , 114:4
9. Deb K. Boruah et al. (2021). Added Value of Diffusion-Weighted Magnetic Resonance Imaging in Differentiating Musculoskeletal Tumors Using Sensitivity and Specificity: A Retrospective Study and Review of Literature. *Cureus* 13(1): e12422. DOI 10.7759/cureus.12422
10. Doaa Mokhtar Mohamed Emara et al. (2014). Is diffusion weighted imaging adding value in diagnosis of focal hepatic lesions? Experience in 50 patients. *Alexandra Journal Of Medicine* 50, 287-301. Available from <http://dx.doi.org/10.1016/j.ajme.2013.03.012>
11. Dr. Subhan Iqbal. 2021. Pigmentend vilonodular synovitis. *Radiopedia*
12. Emilio J. Inarejos Clemente, MD et al. (2020). MRI of Rhabdomyosarcoma and Other Soft-Tissue Sarcomas in Children. *RadioGraphics* ; 40:791–814
13. Govind B. Chavhan et al. (2014). Diffusion-weighted Imaging in Pediatric Body MR Imaging: Principles, Technique, and Emerging Applications. *RadioGraphics* 2014; 34:E73–E88
14. Jae sung yun et al. 2020. Peripheral nerve sheath tumor: differentiation of malignant from benign tumors with conventional and diffusion-weighted MRI. *European Society of Radiology*.
15. JimS.Wu,MD et al. (2009). Soft-Tissue Tumors and Tumorlike Lesions: A Systematic Imaging Approach. *Radiology: Volume 253: Number 2—November 2009* ▪ radiology.rsna.org

16. Joon Hyuk Choi, MD, PhD et al. (2021). The 2020 WHO Classification of Tumors of Soft Tissue: Selected Changes and New Entities. *Adv Anat Pathol* Volume 28, Number 1.
17. Laura W. Bancroft et al. (2002). Intramuscular Myxoma: Characteristic MR Imaging Features. *AJR* ;178:1255–1259
18. L Van der Heijden et al. 2012. The management of diffuse type giant cell tumor (pigmented villonodular synovitis) and giant cell tumor of tendon sheath (nodular tenosynovitis). Available from : <https://pubmed.ncbi.nlm.nih.gov/22733940>
19. Marwa Romeih et al. 2018. The diagnostic value of diffusion-weighted magnetic resonance imaging in characterization of musculoskeletal soft tissue tumors. *Egyptian Society of Radiology and Nuclear Medicine*.
20. Mayo Clinic . (2014). Types of Biopsy Procedures Used to Diagnose Cancer. United States. Available from : <http://www.mayoclinic.org/disease-conditions/cancer/in-depth/biopsy/ART-20043922>
21. Michael E. Kallen, MD et al. (2021). The 2020 WHO Classification What's New in Soft Tissue Tumor Pathology?. *Am J Surg Pathol* Volume 00
22. Muh farid et al. 2014. Malignant peripheral nerve sheath tumor. *The oncologist* 2014;19:193–201
23. Omar A. Hassanien et al. 2018. Diffusion weighted MRI of soft tissue masses: Can measurement of ADC value help in the differentiation between benign and malignant lesions?. *The Egyptian Journal of Radiology and Nuclear Medicine* 49 681–688
24. Orthopaedics and sports medicine. (2022). Soft Tissue Masses. Available from : <https://orthop.washington.edu/patient-care/articles/oncology/soft-tissue-masses.html>
25. Paul L. Mallinson et al. (2014). Radiology of soft tissue tumor. *Surg Oncol Clin N Am* 23 911–936
26. S. Sun et al, 2019. How to differentiate uterine leiomyosarcoma from leiomyoma with imaging. Published by Elsevier Masson SAS.
27. Suzuki A et al. 2019. Differential Diagnosis of Uterine Leiomyoma and Uterine Sarcoma Using Magnetic Resonance Images: A Literature Review. Available at : www.mdpi.com/journal/healthcare
28. The Royal College of Pathologist. (2022). Histopathology. Available from : <https://www.rcpath.org/discoverpathology/news/factsheets/histopathology.html>
29. Tingting Wang et al (2014). Role of apparent diffusion coefficients with diffusion-weighted magnetic resonance imaging in differentiating between benign and malignant bone tumors. *World Journal of Surgical Oncology* , 12:365
30. Ty K. Subhawong, MD et al. (2014). Diffusion-weighted MR Imaging for Characterizing Musculoskeletal Lesions. *RadioGraphics* ; 34:1163–1177
31. Ty K. Subhawong et al. (2010). Soft-Tissue Masses and Masslike Conditions: What Does CT Add to Diagnosis and Management? *AJR Am J Roentgenol*. 2010 June ; 194(6): 1559–1567
32. Vinit Baliyan et al . (2016). Diffusion weighted imaging: Technique and applications. *World J Radiol* 2016 September 28; 8(9): 785-798. available from: URL: <http://www.wjgnet.com/1949-8470/full/v8/i9/785.htm> DOI: <http://dx.doi.org/10.4329/wjr.v8.i9.785>

33. William J. Anderson, Vickie Y. Jo. (2019). Pleomorphic liposarcoma: Updates and current differential diagnosis. *Seminars in Diagnostic Pathology*, <https://doi.org/10.1053/j.semdp.2019.02.007>
34. Xibiao Yang et al. 2021. Case Report: Extra-Articular Diffuse Tenosynovial Giant Cell Tumor of the Temporomandibular Joint. *Frontiers in Oncology*
35. Yeliz Pekcevik et al. (2015). Characterization of Soft Tissue Tumors by Diffusion-Weighted Imaging. *Iran J Radiol.* July; 12(3): e15478.

LAMPIRAN 1


KEMENTERIAN PENDIDIKAN, KEBUDAYAAN, RISET DAN TEKNOLOGI
UNIVERSITAS HASANUDDIN FAKULTAS KEDOKTERAN
KOMITE ETIK PENELITIAN UNIVERSITAS HASANUDDIN
RSPTN UNIVERSITAS HASANUDDIN
RSUP Dr. WAHIDIN SUDIROHUSODO MAKASSAR
 Sekretariat : Lantai 2 Gedung Laboratorium Terpadu
 JL.PERINTIS KEMERDEKAAN KAMPUS TAMALANREA KM.10 MAKASSAR 90245.
 Contact Person: dr. Agussalim Bukhari, MMed,PhD, SpGK TELP. 081241850858, 0411 5780103, Fax : 0411-581431

REKOMENDASI PERSETUJUAN ETIK

Nomor : 527/UN4.6.4.5.31/ PP36/ 2022

Tanggal: 19 September 2022

Dengan ini Menyatakan bahwa Protokol dan Dokumen yang Berhubungan Dengan Protokol berikut ini telah mendapatkan Persetujuan Etik :

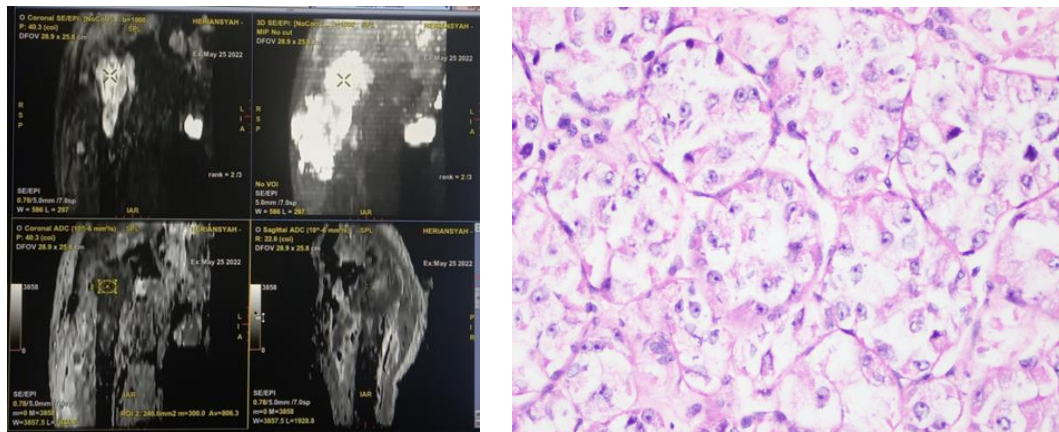
No Protokol	UH22080475		No Sponsor	
Peneliti Utama	dr. ROSMINI AMIN		Protokol	
Judul Peneliti	AKURASI NILAI ADC MRI DALAM MENENTUKAN MALIGNITAS PADA TUMOR JARINGAN LUNAK			
No Versi Protokol	1	Tanggal Versi	24 Agustus 2022	
No Versi PSP		Tanggal Versi		
Tempat Penelitian	RSUP Dr. Wahidin Sudirohusodo Makassar			
Jenis Review	<input type="checkbox"/> Exempted <input checked="" type="checkbox"/> Expedited <input type="checkbox"/> Fullboard Tanggal	Masa Berlaku	Frekuensi review lanjutan	
Ketua KEP Universitas Hasanuddin	Nama Prof.Dr.dr. Suryani As'ad, M.Sc.,Sp.GK (K)	Tanda tangan		
Sekretaris KEP Universitas Hasanuddin	Nama dr. Agussalim Bukhari, M.Med.,Ph.D.,Sp.GK (K)	Tanda tangan		

Kewajiban Peneliti Utama:

- Menyerahkan Amandemen Protokol untuk persetujuan sebelum di implementasikan
- Menyerahkan Laporan SAE ke Komisi Etik dalam 24 jam dan dilengkapi dalam 7 hari dan Laporan SUSAR dalam 72 Jam setelah Peneliti Utama menerima laporan
- Menyerahkan Laporan Kemajuan (progress report) setiap 6 bulan untuk penelitian resiko tinggi dan setiap setahun untuk penelitian resiko rendah
- Menyerahkan laporan akhir setelah Penelitian berakhir
- Melaporkan penyimpangan dari prokol yang disetujui (protocol deviation / violation)
- Mematuhi semua peraturan yang ditentukan

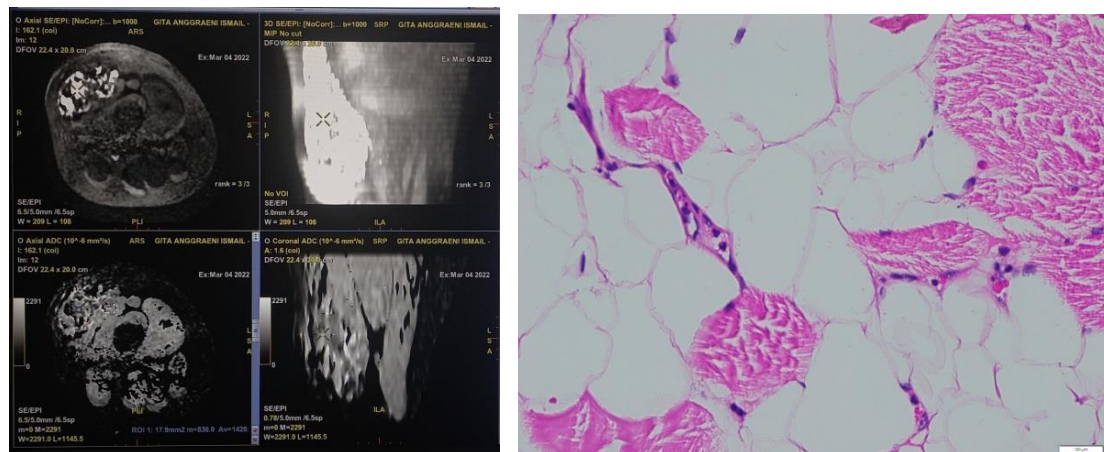
LAMPIRAN 2

CONTOH PEMERIKSAAN DWI/ADC MRI UNTUK TUMOR GANAS



ALVEOLAR SOFT PART SARCOMA

CONTOH PEMERIKSAAN DWI/ADC MRI UNTUK TUMOR JINAK



INTRAMUSKULAR LIPOMA

LAMPIRAN 3

DATA SAMPEL PENELITIAN TUMOR GANAS

NO	NAMA	JK (L/P)	USIA (THN)	LOKASI PEMERIKSAAN MRI	NILAI ADC (10^{-3} mm ² /s)	HASIL PA (JINAK/GANAS)	DIAGNOSIS HISTOPATOLOGI
1	MU	L	40	FEMUR	1.723×10^{-3}	GANAS	MYXOID LIPOSARCOMA HIGH GRADE
2	HE	L	37	LUMBOSAKRAL	0.715×10^{-3}	GANAS	MALIGNANT PERIPHERAL NERVE SHEAT TUMOR
3	NF	L	19	PELVIS	0.432×10^{-3}	GANAS	MALIGNANT ROUND SEL TUMOR
4	AS	L	51	CRURIS	0.474×10^{-3}	GANAS	LIPOSARCOMA
5	SU	L	43	SHOULDER	0.988×10^{-3}	GANAS	LOW GRADE FIBROSARCOMA
6	NR	P	49	FEMUR	1.597×10^{-3}	GANAS	LIPOSARCOMA
7	AK	L	22	HUMERUS	0.556×10^{-3}	GANAS	RHABDOMYOSARCOMA
8	MA	P	74	FEMUR	1.124×10^{-3}	GANAS	HIGH GRADE SARCOMA
9	NH	P	39	FEMUR	0.669×10^{-3}	GANAS	HIGH GRADE SARCOMA
10	FA	L	26	HIP JOINT	0.595×10^{-3}	GANAS	MALIGNANT ROUND CELL TUMOR
11	FI	L	53	CRURIS	0.866×10^{-3}	GANAS	UNDIFERENTIATED PLEOMORPHYC SARCOMA
12	AL	L	42	HUMERUS	1.076×10^{-3}	GANAS	LIPOSARCOMA
13	HR	L	29	HIP JOINT	0.806×10^{-3}	GANAS	ALVEOLAR SOFT PART SARCOMA
14	MR	L	56	GENU	0.801×10^{-3}	GANAS	UNDIFERENTIATED PLEOMORPHYC SARCOMA

15	AB	L	38	FEMUR	1.177×10^{-3}	GANAS	PLEOMORPHYC RHABDOMYOSARCOMA
16	ZA	L	52	CRURIS	0.411×10^{-3}	GANAS	PLEOMORPHYC RHABDOMYOSARCOMA
17	ST	P	35	FEMUR	1.505×10^{-3}	GANAS	LIPOSARCOMA
18	SG	L	70	FEMUR	2.825×10^{-3}	GANAS	PLEOMORPHYC LIPOSARCOMA
19	NN	P	33	FEMUR	1.164×10^{-3}	GANAS	ALVEOLAR SOFT PART SARCOMA
20	AD	L	21	PEDIS	1.094×10^{-3}	GANAS	ALVEOLAR SOFT PART SARCOMA
21	AR	L	17	PELVIS	1.01×10^{-3}	GANAS	MALIGNANT TUMOR SESUAI UNTUK SARCOMA
22	MF	L	49	FEMUR	1.372×10^{-3}	GANAS	EKSTRASKELETAL MYXOID CHONDROSARCOMA
23	SG	L	29	PELVIS	0.673×10^{-3}	GANAS	LIMPHOMA MALIGNA
24	ST	P	59	FEMUR	0.772×10^{-3}	GANAS	PLEOMORPHYC SARCOMA
25	EK	L	36	PELVIS	0.532×10^{-3}	GANAS	MALIGNANT ROUND SEL TUMOR

DATA SAMPEL PENELITIAN TUMOR JINAK

NO	NAMA	JK (L/P)	USIA (THN)	LOKASI PEMERIKSAAN MRI	NILAI ADC (10^{-3} mm ² /s)	HASIL PA (JINAK/GANAS)	DIAGNOSIS HISTOPATHOLOGI
1	HT	L	28	FEMUR	2.324×10^{-3}	JINAK	NEUROFIBROMA
2	RW	P	42	GENU	2.755×10^{-3}	JINAK	DIFFUSE TYPE GIANT CELL TUMOR
3	NB	P	54	GENU	1.354×10^{-3}	JINAK	DIFFUSE TYPE GIANT CELL TUMOR
4	HP	L	60	MANUS	2.755×10^{-3}	JINAK	GANGLION CYST
5	KS	P	45	PELVIS	0.956×10^{-3}	JINAK	LEYMIOMA UTERI
6	HI	P	64	PEDIS	1.942×10^{-3}	JINAK	FIBROLIPOMA PLANTAR PEDIS
7	GA	P	27	FEMUR	1.42×10^{-3}	JINAK	LIPOMA INTRAMUSCULAR
8	NL	P	9	THORAX	1.603×10^{-3}	JINAK	HEMANGIOMA
9	SI	P	12	SHOULDER	1.464×10^{-3}	JINAK	FIBROMATOSIS
10	UD	P	19	FEMUR	1.405×10^{-3}	JINAK	LIPOMA
11	MP	L	15	HUMERUS	0.777×10^{-3}	JINAK	TENOSYNOVIAL GIANT CELL TUMOR,

LAMPIRAN 4

CURRICULUM VITAE

A. Data Pribadi

Nama : dr. Rosmini Amin
Tempat/Tanggal Lahir : Bau-Bau, 12 September 1986
Alamat : BTN NTI jln. Rambutan Blok O no 8
Agama : Islam

B. Riwayat Pendidikan

- SD : SDN 2 BATARAGURU, Lulus tahun 1998
- SMP : SMP NEGERI 2 BAU BAU, Lulus tahun 2001
- SMA : SMA 5 MAKASSAR, Lulus tahun 2004
- Pendidikan Dokter : FK Universitas Muslim Indonesia, Lulus tahun 2012
- Program Pendidikan Dokter Spesialis-1 : Departemen Radiologi Fakultas Kedokteran Universitas Hasanuddin, Makassar, Periode Januari 2019

C. Riwayat Pekerjaan

- Dokter PTT Pusat Puskesmas Totikum, Bangkep, Tahun 2012-2014
- Dokter PTT Pusat Puskesmas Liang, Bangkep, Tahun 2014-2015
- Rumah Sakit Trikora Salakan, Tahun 2016-2018

D. Riwayat Keluarga

- Ayah : Alm. H. Muh.Amin
- Ibu : HJ. Sarniati
- Saudara Kandung : Indriani, S.Kep, Ners dan Firdaus
- Suami : Bayu Lelono Ajie, S. Kom