

Case Report

Posterior Approach in Management of Phacomorphic Angle Closure

Andi Muhammad Ichsan^{a, b} Gerald Ayub Fujiwan Tombe^b
Anastasia Vanny Launardo^b Junely Vimala Jaury^b Andi Pratiwi^{a, b}
Ririn Nislawati^a Nurul Magfirah Rusli Sumara^a Itzar Chaidir Islam^a

^aDepartment of Ophthalmology, Hasanuddin University, Makassar, Indonesia;

^bOphthalmology Unit, SILOAM Hospital, Makassar, Indonesia

Keywords

Posterior lensectomy · Phacomorphic angle closure · Anterior chamber depth

Abstract

This article presents a case of posterior lensectomy through 3-port pars plana vitrectomy for the management of phacomorphic angle closure. A 67-year-old man presented to the outpatient department with headache and decreased vision in his left eye for the past 3 days. Visual acuity 2/60, intraocular pressure (IOP) >60 mm Hg, and the anterior chamber (AC) depth Van Herick grade 1. A complete ophthalmologic examination revealed a phacomorphic angle closure. Serial management was performed consisting of mannitol 20% intravenously, laser peripheral iridotomy, and trabeculectomy. However, the depth of the AC became more shallow, and the IOP remained high. Lens extraction as definitive therapy could not be performed because of the adhesion of the iris and anterior lens capsule to the corneal endothelium; thus, posterior lensectomy using 3-port pars plana vitrectomy, and phacofragmatome was performed. Once the corneal thickness was returned to normal, and the AC depth was sufficient, the patient underwent secondary intraocular lens implantation. A significant improvement in visual acuity, normal IOP, and AC depth were achieved after the management of the posterior approach. Thus, this posterior approach should be considered a good option of management technique in cases with phacomorphic angle closure with very shallow AC depth and a fragile cornea.

© 2021 The Author(s).
Published by S. Karger AG, Basel

Introduction

Phacomorphic angle closure, also known as phacomorphic glaucoma, is a lens-induced secondary angle-closure glaucoma that can occur as a result of the formation of immature cataract. Narrowing of the angle can occur slowly, with the formation of the bulging lens resulting from pushing the iris forward, which leads to obstruction of aqueous flow between the iris and the anterior capsule of the lens. Initial treatment for this pathological condition is targeted at rapidly reducing intraocular pressure (IOP) to prevent further damage to the optic nerve, to clear the cornea, and to prevent synechiae formation. The reduction in IOP is necessary to prepare the patient for laser iridotomy, which relieves the pupillary block and restores the aqueous flow [1]. A longer duration of increased IOP has been found to be correlated with the progression of glaucoma [2–4].

Factors related to phacomorphic angle closure are older age, shallow anterior chamber (AC), thicker and anterior position of the lens, shorter axial length, and high hyperopic status. Lens-induced glaucoma not only might cause a huge and acute rise of IOP but also can pose challenges intraoperatively [4, 5].

The definitive treatment of phacomorphic angle closure is cataract extraction, but this procedure is difficult because of anatomical problems such as corneal edema, shallow AC, nondilating pupil, and weak zonule. High vitreous pressure in such eyes can result in a radial tear of capsulorrhexis, iris prolapse, zonular dialysis, or posterior capsule rupture with subsequent vitreous loss or nucleus drop into the vitreous cavity and, in the worst case, may result in suprachoroidal hemorrhage. The loss of corneal endothelial cells is a major concern as it can lead to severe visual loss due to permanent corneal edema [3, 4].

In very rare occasions in which the AC depth is insufficient, an anterior approach of cataract extraction cannot be safely performed. Herein, we report a different approach of posterior lensectomy using 3-port pars plana vitrectomy for the management of phacomorphic angle closure.

This work has been reported in line with the improved SCARE checklist (see online suppl. Material 1; for all online suppl. material, see www.karger.com/doi/10.1159/000518056). The SCARE guidelines were published in 2016 and modified in 2018 to provide a structure for surgical reports [6].

Case Presentation

A 67-year-old man presented to the outpatient department with painful decreased vision in his left eye for the past 3 days. He had no history of trauma but did have a history of diabetes and hypertension, which were currently controlled with treatment. Ophthalmology examinations revealed a visual acuity of 20/20 and 2/60 in the right and left eyes, respectively. The IOP (as measured by the Topcon Medical Systems CT-80 noncontact computerized tonometer) and other structures in the right eye were normal with pseudophakic status, whereas we noted an extremely high IOP (>60 mm Hg) in the left eye. Anterior segment examination in the right eye was found pseudophakic with IOL in central position, other structures were normal. Gonioscopy on the right eye was open (trabecular meshwork seen in 4 quadrants). The left eye revealed ciliary injections, corneal edema, shallow AC (Van Herick grade 1), sluggish irregular pupil and thickened and forward displacement of the lens. The gonioscopic examination was unclear due to corneal edema. Anterior segment optical coherence tomography in the left eye exhibited a narrowed iridocorneal angle (shown in Fig. 1a, b).

Initial therapy consisted of a combination of β -blocker and corticosteroid topical medications as well as oral carbonic anhydrase inhibitor, which addressed the acute nature of the

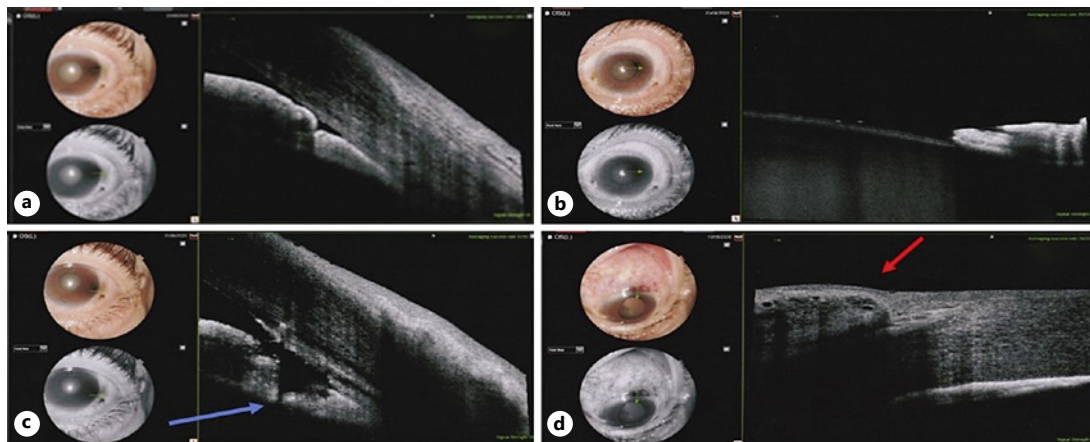


Fig. 1. **a** AS-OCT in the left eye revealed a narrowed iridocorneal angle due to forward displacement of the lens and iris. **b** Anterior lens capsule adhered to the posterior iris. **c** A small hole connected to the posterior chamber to the AC, as indicated by a blue arrow. **d** Filtering bleb after trabeculectomy surgery as indicated by the red arrow. AS-OCT, anterior segment optical coherence tomography; AC, anterior chamber.

angle closure and successfully lowered the patient's IOP to 55 mm Hg with a visual acuity 20/60. However, the IOP rose again, and his visual acuity dropped to 1/60 3 days later. After ensuring normal renal function, intravenous mannitol 20% was given immediately, followed by laser peripheral iridotomy (shown in Fig. 1c). A filtering trabeculectomy with antimetabolites (5-fluorouracil for 5 min) was performed within 5 days, which successfully lowered the patient's IOP to 19 mm Hg, improved visual acuity to 20/60, and resulted in well-functioning bleb (shown in Fig. 1d) and minimal corneal edema, and deepened the AC. We scheduled lens extraction through phacoemulsification and implantation of intraocular lens (IOL); unfortunately, the AC was noted to be extremely shallow during the week after trabeculectomy. Anterior segment optical coherence tomography revealed lenticulo-irido-endothelial touch (shown in Fig. 2) and thickened central corneal thickness (CCT) to 814 μm , and the patient's IOP was >60 mm Hg. This pathological condition was considered due to aqueous humor misdirection (malignant glaucoma) and led to an inability to accomplish phacoemulsification for cataract extraction, so a posterior approach should be considered as one technique for safe and reliable management.

The following day, a vitreoretinal surgeon performed posterior lensectomy using 3-port pars plana vitrectomy under general anesthesia (shown in Fig. 3). The surgical technique involved making 3-port 23-gauge sclerotomies 4 mm from the cornea-scleral limbal, and core and complete vitrectomy resulted in a lower IOP, which allowed for the construction of a main port through a clear corneal incision, reformed the AC depth and released the lenticulo-irido-endothelial adhesion by an ophthalmic viscosurgical device. To avoid friction between the lens and corneal endothelium, we performed posterior lensectomy once the AC depth allowed for sufficient space. We paid careful attention while performing lensectomy manipulation to avoid further zonular dehiscence that was seen from 10 to 12 o'clock. Harder fragments of the nucleus were intentionally dropped into the vitreous cavity and then completely removed using a phacofragmatome. We observed obvious significant corneal clarity and deepened AC intraoperatively. The eye was left aphakic with adequate anterior capsule support for further secondary IOL implantation in the sulcus when the CCT reached the normal limit (shown in Fig. 4).

The most recent ophthalmology examination after 8 months post-surgery revealed remarkable improvement in visual acuity of 20/50, with an IOP of 18 mm Hg, clear cornea,

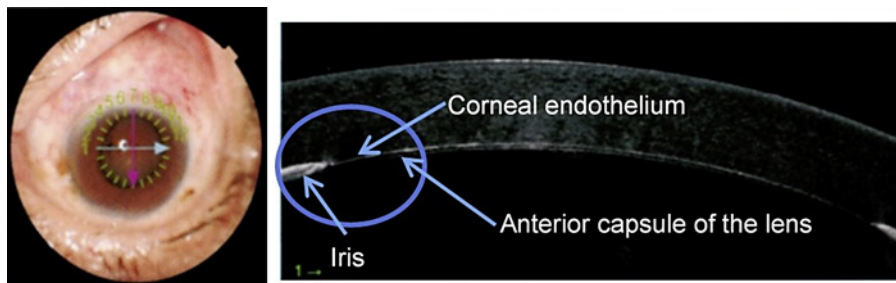


Fig. 2. One week after trabeculectomy, AS-OCT showed an extremely shallow AC depth with lenticulo-irido-endothelial adhesion. AC, anterior chamber.

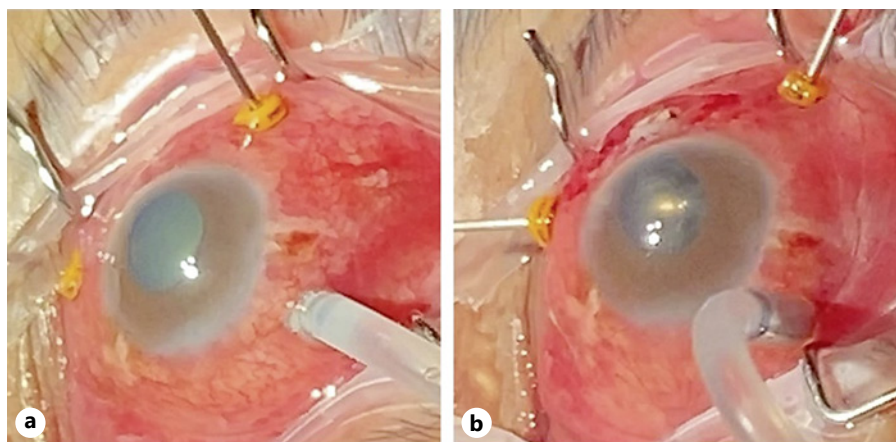


Fig. 3. **a** Three-port pars plana vitrectomy was performed by a vitreoretinal surgeon (AMI). **b** Posterior lensectomy was performed once the AC depth has sufficient space to avoid friction between the lens and corneal endothelium. AC, anterior chamber.

normal AC depth (Van Herick grade 4), and central IOL position. Based on the Indiana Bleb Appearance Grading Scale system, we observed a flat bleb and results of the OCT revealed fibrotic sclera. Subjectively, the patient also stated a significant postsurgical improvement in both visual acuity and relevant symptoms without glaucoma medication.

Discussion/Conclusion

Proper management of the phacomorphic angle closure is urgent, very challenging and requires deep consideration in many critical circumstances [2, 7]. The glaucomatous eye may possess a shallow AC, sluggish pupil, floppy iris syndrome, and zonular instability, which potentially increased the surgical risks during cataract extraction [3, 7, 8]. The strategies of surgery are either glaucoma or cataract surgery first or one setting glaucoma cataract surgery. The option of an anterior or posterior approach can be used especially for cataract extraction.

The risk of rapidly progressive glaucoma and medically uncontrolled disease may warrant a priority surgical intervention [3, 7, 8]. Established studies have mentioned that cataract extraction is the definitive treatment for phacomorphic angle closure [2–4]. The

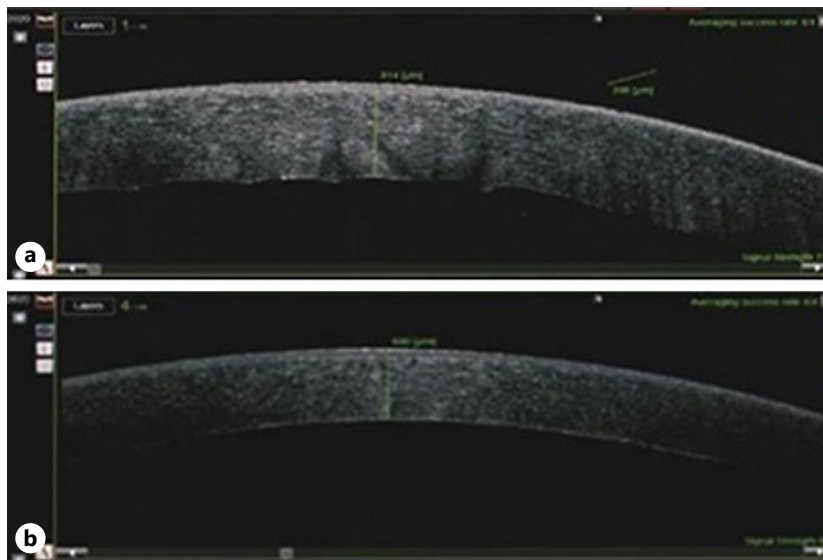


Fig. 4. **a** On the first day after surgery, AS-OCT revealed thickened CCT to 814 μm . **b** After 3 weeks, AS-OCT showed normal AC depth after posterior lensectomy through 3-port pars plana vitrectomy, and the thickened CCT decreased to 600 μm . AC, anterior chamber; CCT, central corneal thickness.

decision to perform lens extraction should be individualized based on several factors other than the effect of IOP. These factors include the patient's characteristics, the surgeon's skills and preferences, status of glaucoma control, and the density of the cataract. Patient characteristics are related to general health, ocular and systemic comorbidities, compliance with glaucoma treatment, visual needs, and prognosis [2, 3, 9].

In this case, the patient had systemic comorbidities of diabetes and hypertension. Anti-glaucoma medication as well as LPI and trabeculectomy were effective in reducing IOP only in the short term. All treatments failed to achieve an adequate AC depth for the phacoemulsification procedure. The close proximity of the phaco tip during nucleus emulsification might increase the risk of corneal endothelial cell loss.

Another important factor to be considered is the surgeon's skill and preferences. Most ophthalmologists are able to perform a relatively safe cataract surgery, and only a few are able to cope with turbulences that occur after glaucoma surgical intervention. Some surgeons may wish to perform an easier procedure that offers a certain amount of IOP lowering, less risk, short recovery, and faster visual rehabilitation. Cataract extraction from the phacomorphic angle closure is associated with unpredictable intraoperative difficulties. The crowded AC disturbs the surgical manipulation of phacoemulsification in such eyes. The peripheral iridocorneal apposition makes it difficult to properly construct a clear corneal incision. The shallow AC puts the cornea under a higher risk of damage by ultrasound waves and/or mechanical contact of the surgical instruments. In addition, corneal edema and pupillary abnormalities may increase the difficulty of capsulorrhexis. Consequently, clear cornea phacoemulsification is considered to be fraught with a higher risk of intra- and post-operative complications. In such instances, pars plana vitrectomy combined with posterior lensectomy might be a relatively safer method of manipulation [10, 11]. Performing vitrectomy to remove the vitreous is considered the only promising method for successfully deepening the AC. In this case, a vitreoretinal surgeon (AMI) performed posterior lensectomy through 3-port pars-plana vitrectomy because of the extremely shallow depth of the AC, higher positive vitreous pressure, and thickened CCT.

The implantation of an IOL after the first procedure depends on the intactness of the lens capsule and stability of the zonules. Calculating the IOL power might be affected by corneal curvature, AC depth, and axial length, which are positively correlated with changes in IOP after trabeculectomy [8, 10, 12]. With regard to stable zonular support, the secondary IOL (monofocal hydrophilic acrylic foldable type) was implanted in the sulcus 3 weeks after posterior lensectomy using a clear corneal incision. In conclusion, posterior lensectomy using the 3-port pars plana vitrectomy approach for the management of phacomorphic angle closure should be considered and is highly recommended when the AC is inadequate for performing cataract extraction anteriorly.

Acknowledgements

The author would like to thank and appreciate the team of nurses and staff of Siloam Hospital who were involved in the preparation, treatment and operation of this patient.

Statement of Ethics

This study protocol was reviewed, and the need for approval was waived by The Ethics Committee of Medical Research, Faculty of Medicine, Hasanuddin University (Approval number: 208/UN4.6.4.5.31/PP36/2021). Written informed consent was obtained from the patient for publication of this case report and any accompanying images.

Conflict of Interest Statement

The authors state there is no conflict of interest in writing this article.

Funding Sources

This manuscript did not receive any funding.

Author Contributions

A.M.I.: conception or design of the work, performing the medical operation, analysis and interpretation of data for the work, and drafting the work. G.A.F.T., A.V.L., R.N., and J.V.J.: performing the medical operation as a team, caring for patients, performing follow-up after surgery, and drafting the work. A.P., N.M.R.S., and I.C.I.: drafting the work and revising it critically for important intellectual content.

Data Availability Statement

All data generated or analyzed during this study are included in this article and its online suppl. material files. Further inquiries can be directed to the corresponding author.

References

- 1 Nolan WP, Foster PJ, Devereux JG, Uranchimeg D, Johnson GJ, Baasanhu J. YAG laser iridotomy treatment for primary angle closure in east Asian eyes. *Br J Ophthalmol*. 2000;84(11):1255–9.
- 2 Kaplowitz BK, Kapoor KG. An evidence-based approach to phacomorphic Glaucoma. *J Clin Exp Ophthalmol*. 2011;4(2):1–6.
- 3 Laurenti K, Salim S. Lens-induced glaucoma: diagnosis and management. *Ophthalmic Pearls*; 2016. p. 55–6. Glaucoma.
- 4 Noh HJ, Kim ST. Combined treatment of phacoemulsification and single-port limited pars plana vitrectomy in acute angle-closure glaucoma. *Int J Ophthalmol*. 2019;12(6):974–9.
- 5 Girkin CA, Borade AM, Crowston JG, Giaconi JA, Medeiros FA, Sit AJ, et al. Glaucoma. *Basic and clinical science course, section 10*; 2019. p. 117–28.
- 6 Agha RA, Borrelli MR, Farwana R, Koshy K, Fowler AJ, Orgill DP, et al. The SCARE 2018 statement: updating consensus Surgical CAse REport (SCARE) guidelines. *Int J Surg*. 2018;60:132–6.
- 7 Aung T, Crowston J, Chenshen HL, Covar RVA, George R, Kim SH, et al. Initiation of treatment. *Asia Pacific glaucoma guidelines*; 2009. p. 33.
- 8 Khanifar AA, Roux HK, Chan RVP, Lakhanpal RR, Albin T. Surgical updates: pars plana vitrectomy and lensectomy with a 23-gauge vitrectomy system. *Retin Today*. 2010;34–6.
- 9 McCannel CA, Atebara NH, Kim SJ, Leonard BC, Rosen RB, Sarraf D, et al. Retina and vitreous. *Basic and clinical science course, section 12*; 2017. p. 405–17.
- 10 Moraru A, Pînzaru G, Moțoc A, Costin D. Functional results of cataract surgery in the treatment of phacomorphic glaucoma. *Rom J Ophthalmol*. 2017;61(3):202–6.
- 11 Zhang Z, Zhang S, Jiang X, Qiu S, Wei Y. Surgical outcomes of 23-gauge transconjunctival pars plana vitrectomy combined with lensectomy for glaucomatous eyes with extremely shallow anterior chamber and cataract. *BMC Ophthalmol*. 2016;16(1):2–7.
- 12 Eid TM. Primary lens extraction for glaucoma management: a review article. *Saudi J Ophthalmol*. 2011;25(4):337–45.