

## DAFTAR PUSTAKA

- Alhaji, M., Bansal, P., & Goyal, A. (2020). Physiology, Granulation Tissue. In *StatPearls*.
- Amin, Z. A., Ali, H. M., Alshawsh, M. A., Darvish, P. H., & Abdulla, M. A. (2015). Application of *Antrodia camphorata* Promotes Rat's Wound Healing in Vivo and Facilitates Fibroblast Cell Proliferation in Vitro. *Evidence-Based Complementary and Alternative Medicine*.
- Bainbridge, P. (2013). Wound healing and the role of fibroblasts. *Journal of Wound Care*, 22(8), 407–412.
- Balogh Mary Bath and Margaret J. Fehrenbach. (2011). *Illustrated Dental Embryology, Histology, and Anatomy*.
- Church, J. T., Posluszny, J. A., Hemmila, M., To, K. B., Cherry-Bukowiec, J. R., & Waljee, J. (2015). Methylene blue for burn-induced vasoplegia: Case report and review of literature. In *Journal of Burn Care and Research*.
- Eissa, A. E., Zaki, M. M., Saeid, S., Abdelsalam, M., Ali, H. M., Moustafa, A. A., Ibrahim, T. B., & Abumhara, A. A. (2013). In vitro evaluation of the efficacy of hemodialysate (Solcoseryl®) as a wound healing agent in Nile tilapia (*Oreochromis niloticus*). *International Journal of Veterinary Science and Medicine*.
- Elliott, D. G. (2011). Functional Morphology of the Integumentary System in Fishes. In: Farrell A.P. *Encyclopedia of Fish Physiology: From Genome to Environment*, 1(1), 476–488.
- Fahmi, Melita Rini., Anjang Bangun Prasetyo., R. V. (2015). Potensi Ikan Medaka (*Oryzias woworae*, *O. javanicus* dan *O. profundicola*) sebagai Ikan Hias dan Ikan Model. *Prosiding Seminar Nasional Ikan*, Ke.8, 8.
- Genten, F., Terwinghe, E., & Danguy, A. (2009). Atlas of Fish Histology. In *Atlas of Fish Histology*.
- Guo, X., Xia, B., Lu, X. B., Zhang, Z. J., Li, Z., Li, W. L., Xiong, A. B., Deng, L., Tan, M. Y., & Huang, Y. C. (2016). Grafting of mesenchymal stem cell-seeded small intestinal submucosa to repair the deep partial-thickness burns. *Connective Tissue Research*, 57(5), 388–397.
- Gupta, A., & Kumar, P. (2015). Assessment of the histological state of the healing wound. *Plastic and Aesthetic Research*.
- Handi, P., Sriwidodo, & Ratnawulan, S. (2017). Review Sistematis: Proses Penyembuhan dan Perawatan Luka. *Farmaka Journal*.
- Harsha, L., & Brundha, M. P. (2020). Role of collagen in wound healing. *Drug Invention Today*, 13(1), 55–57.
- Ishikawa, Y. (2000). Medakafish as a model system for vertebrate developmental




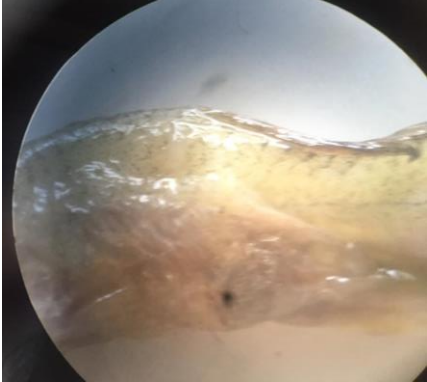


genetics. In *BioEssays*.

- Junqueira, L., & Carneiro, J. (2005). *Basic Histology: Text & Atlas*. Statrefcom.
- Karamichos, D. (2009). Regulation of corneal fibroblast morphology and collagen. *Journal of Tissue Viability*, 33(4), 1–15.
- King, T. C. (2007). Cell Injury, Cellular Responses to Injury, and Cell Death. *Elsevier's Integrated Pathology*, 1–20.
- Kurniawan, Andri. (2012). *Penyakit Akuatik*. UBB Press.
- Martin, P., & Feng, Y. (2009). Inflammation: Wound healing in zebrafish. In *Nature*.
- Marwati., Morina Riauваты., D. H. S. (2015). *Histopathology Of Gill And Brain Of Tilapia (Oreochromis Niloticus) That were Infected with Streptococcus iniae*.
- Mary, K. D. J. H. M. F. L. (2020). Histology, Fibroblast. *StatPearls*.
- Mathuru, A. S. (2016). Conspecific injury raises an alarm in medaka. *Scientific Reports*.
- Mawardi, M. (2016). *Methylene Blue Digunakan Oleh Pembudidaya Untuk Pencegahan Dan Pengobatan Penyakit Ikan Yang Biasanya Ditandai Dengan Borok (Ulcer) Pada Kulit Ikan*. Universitas Terbuka.
- Milyavsky, M., & Dickie, R. (2017). Methylene blue assay for estimation of regenerative re-epithelialization in vivo. *Microscopy and Microanalysis*.
- Mohammed, O., Ibrahim, S., & Ibrahim, O. (2014). *A Comparative Study between Ceftobiprole and Vancomycin in treating Skin and Soft Tissue Infections ( SSTIs ) due to Methicillin Resistant staphylococcus aureusin Mice a A Comparative Study between Ceftobiprole and Vancomycin in treating Skin and Soft Tis. May*.
- Mumford, S., Heidel, J., Smith, C., Morrison, J., Macconnell, B., & Blazer, V. (2007). Fish Histology and Histopathology. In *Journal of Geoscience and Environment Protection*.
- Noga, E. J. (2000). Skin ulcers in fish: Pfiesteria and other etiologies. In *Toxicologic Pathology*.
- Park, I.-S., Baek, S.-W., & Moon, K. H. (2019). The Sterilization Effect of Methylene Blue, Formalin, and Iodine on Egg and Adult Stage of Marine Medaka, *Oryzias dancena*. *Development & Reproduction*.
- Richardson, R., Slanchev, K., Kraus, C., Knyphausen, P., Eming, S., & Hammerschmidt, M. (2013). Adult zebrafish as a model system for cutaneous wound-healing research. *Journal of Investigative Dermatology*.
- Risnawati., Muhammad Ruslan Umar., dan I. A. (2015). *Distrbusi Populasi dan Ekologi Ikan Medaka Oryzias spp. di Perairan Sungai Maros, Kabupaten Maros Sulawesi Selatan*.

- Rosique, M. J., Rosique, R. G., Faria, F. M., Oliveira, C. C., Farina, J. A., & Évora, P. R. B. (2017). Methylene blue reduces progression of burn and increases skin survival in an experimental rat model. *Burns*.
- Sari, Dwi Kesuma., Irma Andriani, Khusnul Yaqin, dan A. M. S. (2018). The Use of Endemic Sulawesi Medaka Fish (*Oryzias celebensis*) as an animal model candidate. *Proc. of the 20th FAVA CONGRESS and The 15th KIVNAS PDHI Bali Nov 1-3*, 1–3.
- Schmidt, J. G. (2013). *Wound healing in rainbow trout (Oncorhynchus mykiss) and common carp (Cyprinus carpio) with a focus on gene expression and wound imaging*. 194.
- Sveen, L. R., Timmerhaus, G., Krasnov, A., Takle, H., Handeland, S., & Ytteborg, E. (2019). Wound healing in post-smolt Atlantic salmon (*Salmo salar* L.). *Scientific Reports*.
- Sveen, L. R., Timmerhaus, G., Krasnov, A., Takle, H., Stefansson, S. O., Handeland, S. O., & Ytteborg, E. (2018). High fish density delays wound healing in Atlantic salmon (*Salmo salar*). *Scientific Reports*.
- USAID. (2018). *The State of The Sea: Indonesia. Volume One An Overview of Marine Resource Management for Small-Scale Fisheries and Critical Marine Habitats in Indonesia*. USAID.
- Vernerey, F. J., & Barthelat, F. (2014). Skin and scales of teleost fish: Simple structure but high performance and multiple functions. *Journal of the Mechanics and Physics of Solids*.
- Woo, K. Y., & Heil, J. (2017). A prospective evaluation of methylene blue and gentian violet dressing for management of chronic wounds with local infection. *International Wound Journal*.

## LAMPIRAN

## Lampiran 1. Dokumentasi Kegiatan

 <p><b>Pengambilan sampel</b></p>	 <p><b>Pemeliharaan ikan</b></p>
 <p><b>Pemberian Perlakuan</b></p>	 <p><b>Setelah Pemberian Luka</b></p>
 <p><b>Proses Fiksasi</b></p>	 <p><b>Proses Dehidrasi</b></p>



**Proses Clearing**



**Embedding**



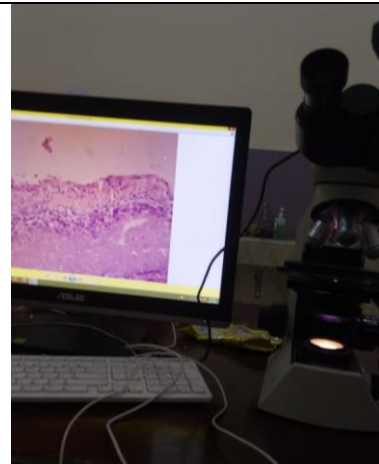
**Pemotongan**



**Pewarnaan**



**Pewarnaan**



**Pembacaan Preparat Histologi**

### Lampiran 2. Prosedur Pembuatan Preparat Histologi

No	Proses	Reagensia	Waktu
1	Fiksasi	Buffer formalin 10%	3 hari
2	<i>End Point</i>	Alkohol 70%	1 hari
3	Dehidrasi	Alkohol 70%	1 hari
4	Dehidrasi	Alkohol 80%	1 hari
5	Dehidrasi	Alkohol 90%	1 hari
6	Dehidrasi	Alkohol 95%	1 hari
7	Dehidrasi	Alkohol 100%	1 jam
8	Dehidrasi	Alkohol 100%	1 jam
9	<i>Clearing</i>	Xylol I	15 menit
10	<i>Clearing</i>	Xylol II	15 menit
11	<i>Infiltrating</i>	Paraffin Cair I	1 jam
12	<i>Infiltrating</i>	Paraffin Cair II	1 jam
<b>Total Waktu</b>			<b>196,5 jam</b>

### Lampiran 3. Prosedur Pewarnaan HE

No	Reagensia	Waktu
1	Xylol I	30 menit
2	Xylol II	15 menit
3	Alkohol 100%	1 menit
4	Alkohol 100%	1 menit
5	Alkohol 95%	1 menit
6	Alkohol 90%	1 menit

7	Alkohol 80%	1 menit
8	Alkohol 70%	1 menit
9	Mayer's Haematoxylin	15 menit
10	Rendam dalam Tap Water I	1 menit
11	Rendam dalam Tap Water II	15 menit
12	Eosin	30 menit
13	Alkohol 70%	30 detik
14	Alkohol 80%	30 detik
15	Alkohol 90%	30 detik
16	Alkohol 95%	30 detik
17	Alkohol 100%	30 detik
18	Alkohol 100%	30 detik
19	Xylol I	30 detik
20	Xylol II	30 detik



Penulis dilahirkan di Alam Buana, Sulawesi Selatan pada tanggal 15 Juni 1998 sebagai anak kedua dari lima bersaudara, dari ayah bernama I Wayan Jasi, S.Pd, M.Si dan ibu bernama Adolpina K, S.Pd. Pendidikan Taman Kanak-kanak penulis diselesaikan di TK Ganesha pada tahun 2004 dan pendidikan Dasar di SDN 173 Sukamaju II pada tahun 2010. Tahun 2013 lulus dari SMPN 1 Sukamaju dan menyelesaikan pendidikan menengah atas di SMAN 1 Sukamaju pada tahun 2016.

Pendidikan di Universitas Hasanuddin Makassar penulis tempuh sejak tahun 2016 melalui jalur JNS dengan memilih Program Studi Kedokteran Hewan, Fakultas Kedokteran Universitas Hasanuddin. Selama perkuliahan penulis aktif dalam organisasi internal kampus yaitu Himpunan Mahasiswa Kedokteran Hewan (HIMAKAHA) periode 2019-2020 menjabat sebagai anggota Bidang Pendidikan dan Penelitian. Selain itu penulis juga aktif berbagai kepanitiaan di dalam kampus. Penulis juga menjabat sebagai asisten Laboratorium Fisiologi Veteriner I dan II dan Satwa Akuatik, Laboratorium Ilmu Teknologi Reproduksi, dan Ilmu Kebidanan dan Kemajiran. Penulis melaksanakan tugas akhir dengan judul penelitian *“Gambaran Histologi Kulit Ikan Medaka Sulawesi (Oryzias celebensis) selama Proses Penyembuhan Luka Tusukan (Puncture Wound)*