


Penile Ischemia as a Complication of Epinephrine Use in Penile Nerve Block: Truth or Myth?


Muhammad Asykar

Palinrungi ¹

Andhini LR

Palinrungi²

Robert Christeven³

Muhammad Faruk ³

¹Division of Urology, Department of Surgery, Faculty of Medicine, Hasanuddin University, Makassar, South Sulawesi, Indonesia; ²Department of Surgery, Akademis Jaury Jusuf Putra Hospital, Makassar, South Sulawesi, Indonesia; ³Department of Surgery, Faculty of Medicine, Hasanuddin University, Makassar, South Sulawesi, Indonesia

Abstract: The administration of a local anesthetic agent with epinephrine is controversial in penile surgery because of necrosis risk resulting from prolonged vasoconstriction of terminal vessels. We reported a case of an 8-year-old boy suffering from ischemia in the glans of the penis and epidermolysis of the penile skin after circumcision with penile nerve block using anesthetic agents containing epinephrine. The addition of epinephrine to the anesthetic agent (lidocaine) in penile nerve block before circumcision remains controversial. It remains controversial because multiple factors can cause skin necrosis after the circumcision. The adverse effect of epinephrine use in circumcision remains unproven because of a lack of scientific evidence. The administration of epinephrine in penile surgery is the decision of the physician.

Keywords: penile ischemia, skin necrosis, nerve block, circumcision, anesthetic agents

Introduction

Local anesthetic agents generally aggravate epinephrine to reduce the concentration of agents in plasma, reducing the likelihood of systemic toxicity. Local anesthetic agents also improve the quality of anesthesia and simultaneously extend the duration of the peripheral nerve block.¹ The administration of a local anesthetic agent with epinephrine is controversial in the surgery of end artery organs, such as the penis and fingers, because of the risk of necrosis resulting from prolonged vasoconstriction of terminal vessels.² However, to our knowledge, no study has thoroughly demonstrated any disastrous effect of epinephrine use in penile nerve block in circumcision.

Case Presentation

An 8-year-old boy suffered significant swelling and blistering of his penis at 24-h post-circumcision. A medical practitioner performed the circumcision. The circumcision was performed using a sterile instrument and suture material (plain catgut 3/0) with circumcision technique and local anesthetic nerve block with lidocaine hydrochloride 20 mg/mL and epinephrine 12.5 mcg/mL per 2 mL ampoule. The anesthetic solution was administered using the penile nerve block technique. The pain sensation and swelling were apparent approximately 1 h after the circumcision and became prominent 3–4 h after circumcision. Five hours after the circumcision, the swelling had worsened, and a blister appeared at the skin of the penile corpus. At 24-h post-circumcision, the swelling had improved, but the blister remained (Figure 1). The penile glans was paler (an ischemic sign), with incarcerating crust. Proper wound care

Correspondence: Muhammad Asykar Palinrungi
Division of Urology, Department of Surgery, Faculty of Medicine, Hasanuddin University, Jalan Perintis Kemerdekaan KM 11, Makassar, South Sulawesi, 90245, Indonesia
Tel +6282187776907
Fax +62411587571
Email apalinrungi@yahoo.com

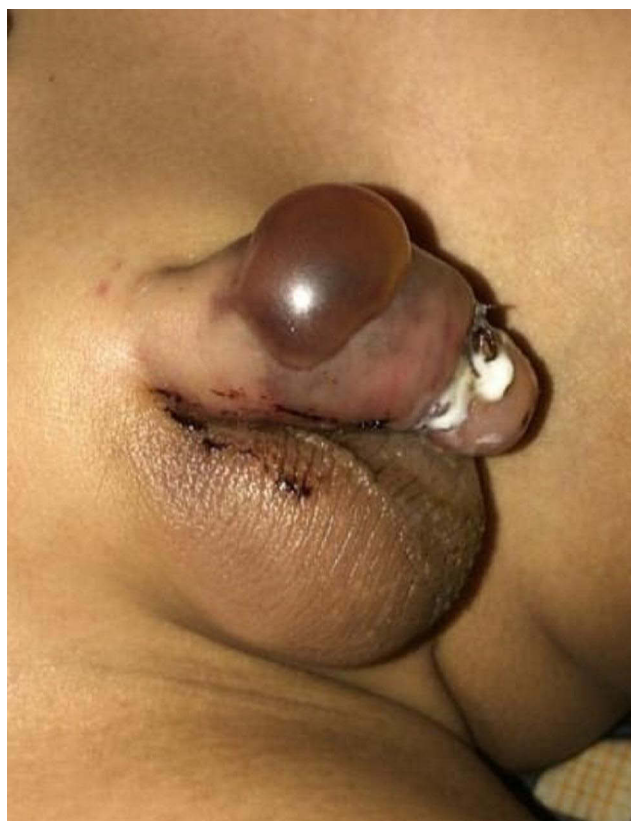

Figure 1 The blister appeared on the penile corpus 24 h after the circumcision.

with normal saline compress and wound crust cleansing was performed. On the second day after the circumcision, the blister had subdued, and the superficial ulcer was observed at the wound bed. On the third day, yellowish-necrotic tissue was observed on the lateral side of the glans (Figure 2). Neither gangrene nor pus was observed at the penis. One week after the circumcision, the wound at the glans and corpus was improved. Four months after the circumcision event, the penis had healed without any cicatrix (Figure 3). There was no disturbance in micturition or erection.

Discussion

Circumcision is a commonly performed procedure in childhood, especially in Indonesia. Failure (4–7%) and complication (1.5–5%) of circumcision can be caused by vascular disturbance, including vasospasm of the penile glans due to surgery or the dorsal penile nerve block, vascular obstruction secondary to the mass effect of anesthetic solution, hematoma at the site of injection, and endothelial injury.³

Anesthesia with peripheral nerve block is the most commonly used anesthesia method in circumcision.² The addition of epinephrine to the anesthetic agent (lidocaine)

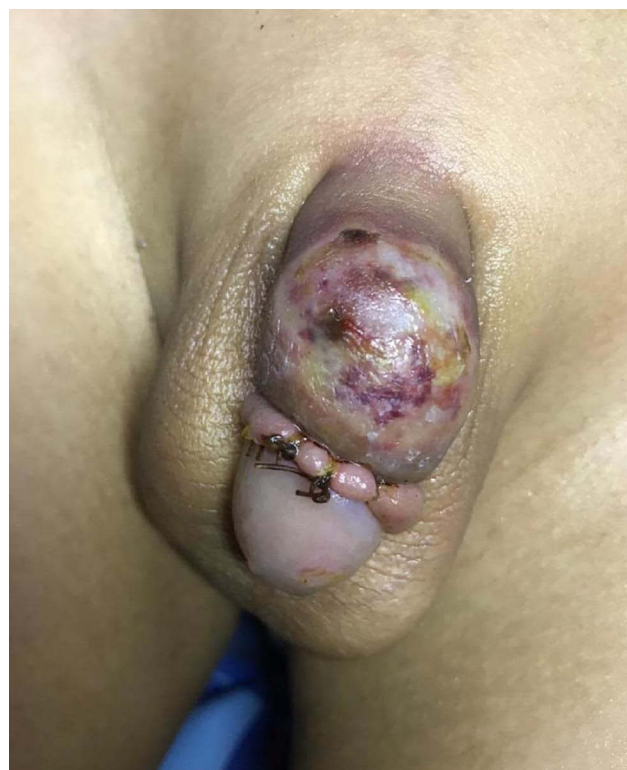

Figure 2 Superficial ulcer at the corpus, yellowish necrotic tissue at the glans, and crust were apparent.

in penile nerve block before circumcision remains controversial. Gul et al reported a case of scrotal skin necrosis as a suspected complication of epinephrine used in circumcision. Still, it remains controversial because multiple factors can cause skin necrosis after the circumcision.⁴ On the other hand, Garrido-Abad and Suarez-Fonseca reported a case of a 3-year-old boy who suffered glans necrosis after circumcision, which was not related to the use of epinephrine in peripheral nerve block (mepivacaine without epinephrine).³

The patient in our case had experienced blistering in the penile corpus skin as a sign of epidermolysis, which can be related to penile skin ischemia. However, it resolved spontaneously without any invasive intervention. In our case, the ischemia of the glans with necrotic tissue was probably caused by incarcerating crust/scab, which could also have happened in the other circumcision cases. It also improved with the treatment of saline compress and crust cleansing. There was no accurate evidence to link the ischemia with epinephrine use. The study by Schnabl et al showed that local anesthetics with epinephrine are safe for use in penile nerve block.²

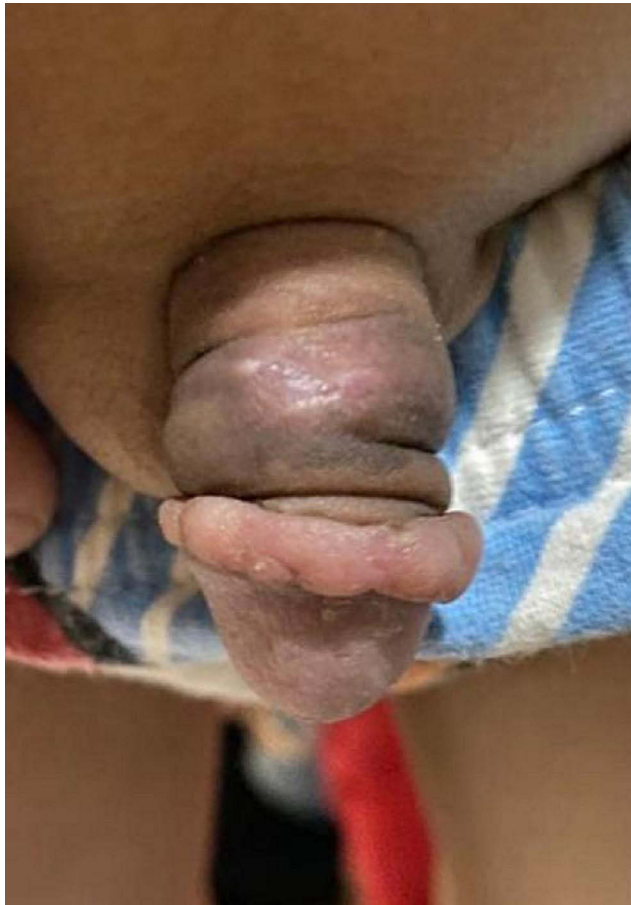


Figure 3 The penile wound healed 4 months after circumcision.

Conclusion

The penile ischemia event in the circumcision could not be confirmed as a complication related to epinephrine use in peripheral nerve block because it could have been caused

by multiple factors. The adverse effect of epinephrine use in circumcision remains unproven because of a lack of scientific evidence. The administration of epinephrine in penile surgery is the decision of the physician.

Ethical Approval

The study is exempt from ethical approval in our institution.

Consent

Written informed consent was obtained from the parent/guardian of the patient for publication of this case report and accompanying images. A copy of the written consent is available for review by the Editor-in-Chief of this journal on request.

Disclosure

The authors report no conflicts of interest for this work.

References

1. Sinnott CJ, Cogswell LP, Johnson A, Strichartz GR. On the mechanism by which epinephrine potentiates lidocaine's peripheral nerve block. *Anesthesiology*. 2003;98(1):181–188. doi:10.1097/0000542-200301000-00028
2. Schnabl SM, Herrmann N, Wilder D, Breuninger H, Häfner HM. Clinical results for use of local anesthesia with epinephrine in penile nerve block. *J der Dtsch Dermatologischen Gesellschaft*. 2014;12(4):332–339. doi:10.1111/ddg.12287
3. Garrido-Abad P, Suarez-Fonseca C. Glans ischemia after circumcision and dorsal penile nerve block: case report and review of the literature. *Urol Ann*. 2015;7(4):541. doi:10.4103/0974-7796.164862
4. Gul M, Kaynar M, Sekmenli T, Ciftci I, Goktas S. Epinephrine injection associated scrotal skin necrosis. *Case Rep Urol*. 2015;2015:3. doi:10.1155/2015/187831

Research and Reports in Urology

Publish your work in this journal

Research and Reports in Urology is an international, peer-reviewed, open access journal publishing original research, reports, editorials, reviews and commentaries on all aspects of adult and pediatric urology in the clinic and laboratory including the following topics: Pathology, pathophysiology of urological disease; Investigation and

treatment of urological disease; Pharmacology of drugs used for the treatment of urological disease. The manuscript management system is completely online and includes a very quick and fair peer-review system, which is all easy to use. Visit <http://www.dovepress.com/testimonials.php> to read real quotes from published authors.

Submit your manuscript here: <https://www.dovepress.com/research-and-reports-in-urology-journal>

Dovepress